

“Non-Diabetic Retinal Vascular Disease”

Brad Sutton, O.D., F.A.A.O.

Clinical Professor

IU School of Optometry

Indianapolis Eye Care Center

Retinal Vascular Disease

- ▶ No financial disclosures

Hypoperfusion Syndrome

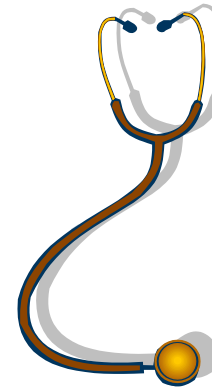
- ▶ Occurs when the eye lacks blood perfusion secondary to carotid artery blockage or ophthalmic artery blockage.
- ▶ Terminology debate: venous stasis retinopathy vs. hypoperfusion syndrome
- ▶ Why is venous stasis retinopathy a poor term for this condition?

Hypoperfusion Syndrome

- ▶ Patient may complain of dull, chronic ache in the affected eye
- ▶ Photostress issues / dazzle
- ▶ TIA symptoms may or may not be present (amaurosis fugax)
- ▶ Possible bruit / decreased pulse strength in carotid


Hypoperfusion Syndrome

- ▶ Bruit at 30-85% blockage; swishing sound
- ▶ Bell vs. diaphragm
- ▶ Definitive diagnosis requires carotid imaging



Hypoperfusion Syndrome

- ▶ Peripheral dot / blot hemorrhages
- ▶ Dilated veins
- ▶ Relatively spares the posterior pole



Ocular Ischemic Syndrome

- ▶ With ocular ischemic syndrome same findings plus.....
 - ▶ NVD / NVE / NVI
 - ▶ Iritis
 - ▶ Sluggish pupil
 - ▶ Conjunctival congestion
 - ▶ Corneal Edema
 - ▶ 80% unilateral / 20% bilateral

Ocular Ischemic Syndrome

- ▶ Rare! Only 10% of eyes with 70+% blocked carotids
- ▶ 60% CF or worse VA by one year: 82% if NVI is present
- ▶ Teichopsia: colored afterimages after viewing lights
- ▶ More likely in patients with increased homocysteine and CRP

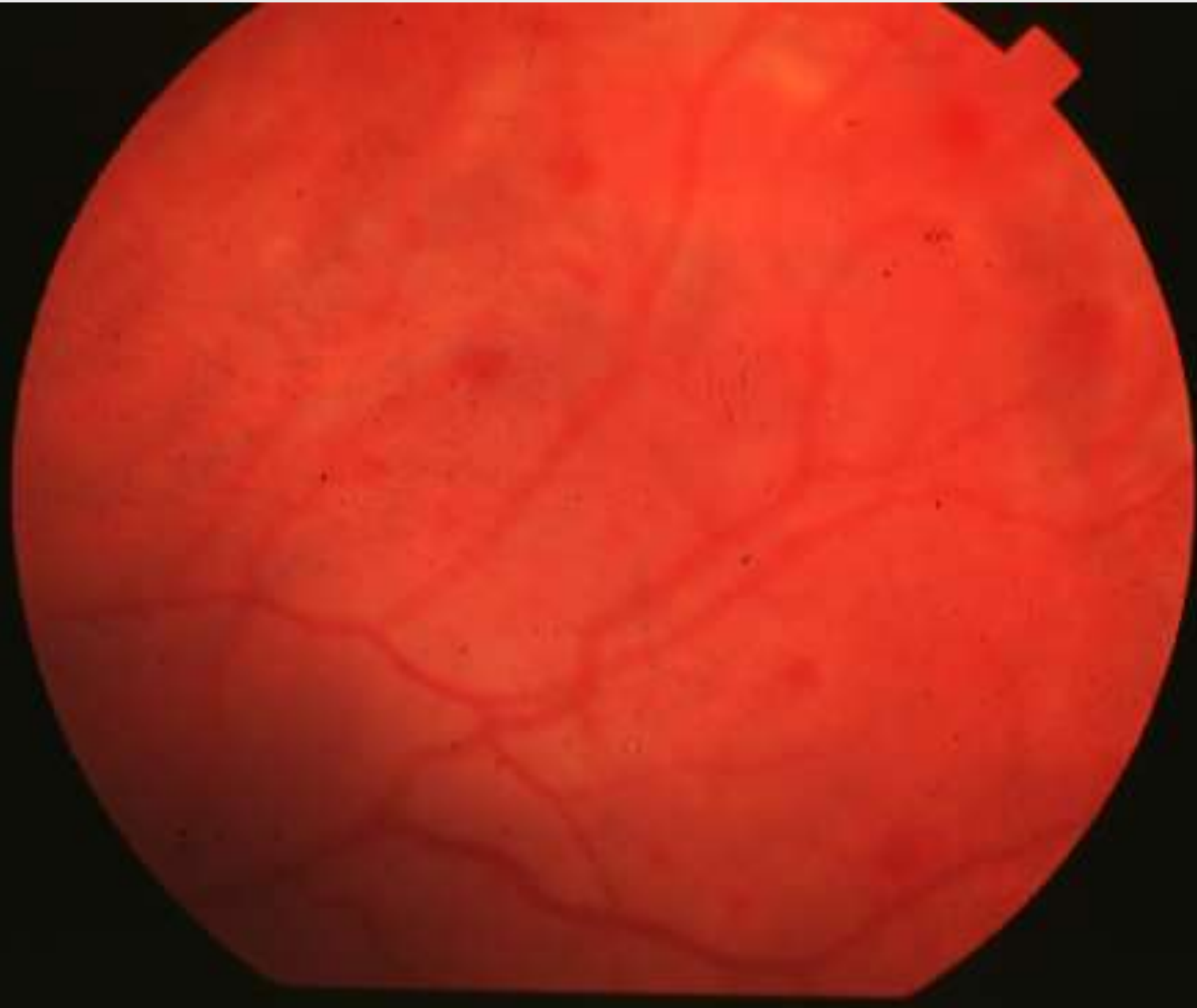
Ocular Ischemic Syndrome

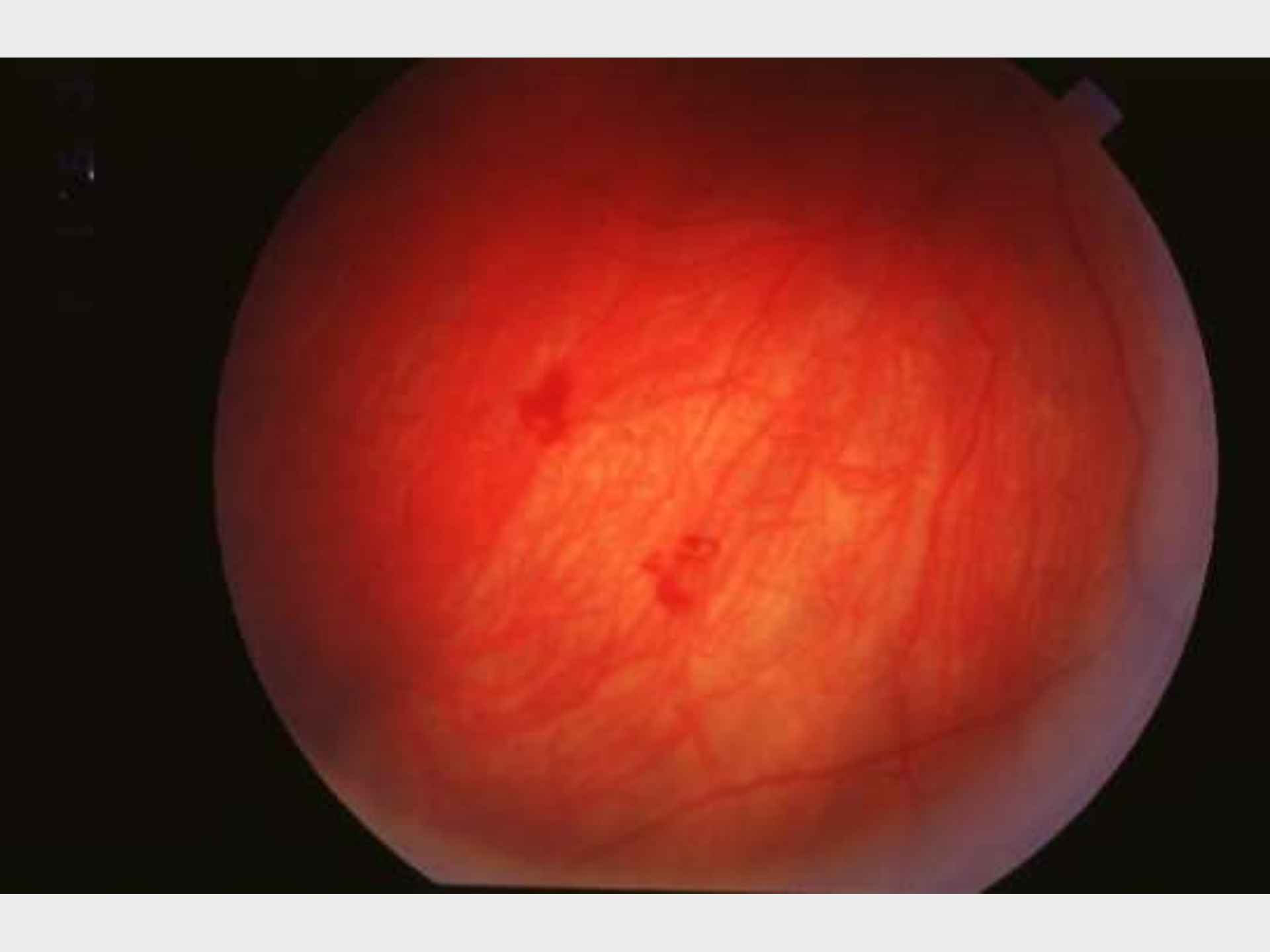
- ▶ When presented with these ocular findings.....
 - ▶ Question about TIA
 - ▶ Check carotids
 - ▶ Arrange for carotid testing (Doppler has limits)
 - ▶ ESR
 - ▶ C-reactive protein
 - ▶ CBC

Ocular Ischemic Syndrome

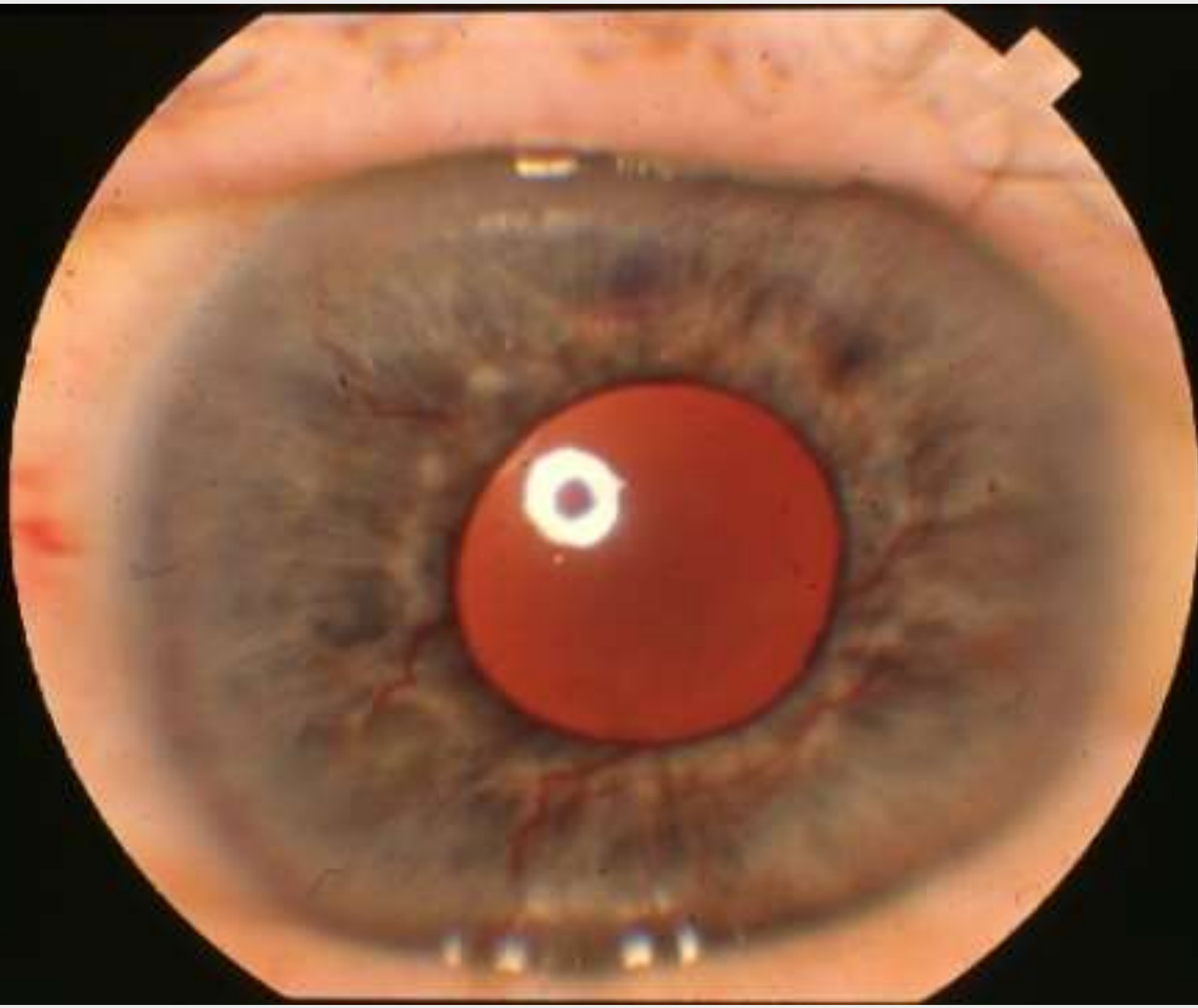
- ▶ Treatment:
 - ▶ Systemic management (diet, drugs, surgery)
 - ▶ PRP / cryotherapy?
 - ▶ Avastin / Lucentis / Eyelea?
 - ▶ Five year mortality rate of 40%

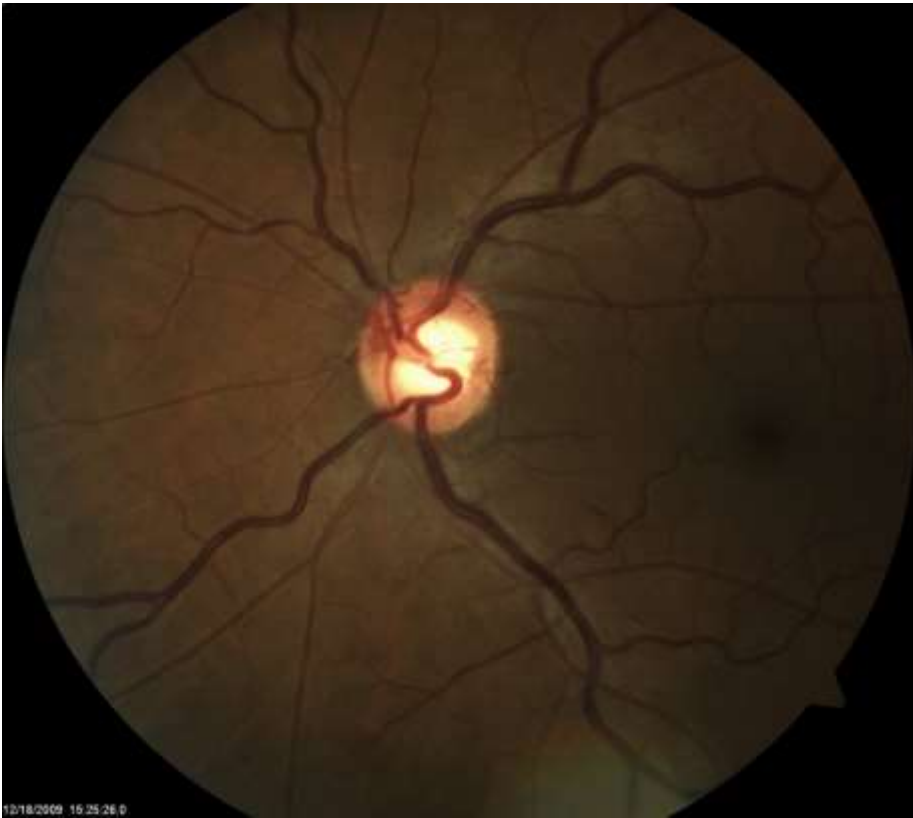0.0.0.A





5390





Sickle Cell Retinopathy


- ▶ Hemoglobinopathy affecting mostly AA (8% in US carry trait, .15% have SS dis.)
- ▶ 60,000 in US: 250,000 born yearly w-wide
- ▶ Malaria and natural selection (sickle trait carriers and sickle cell patients are resistant to malaria)
- ▶ AC, SA, SS, Sthal, SC. All forms autosomal recessive. A is normal hemoglobin
- ▶ Improper amino acid substitutions

Sickle Cell

- ▶ RBC's become sickle shaped
- ▶ RBC's get trapped > hypoxia > ischemia > more sickling = cycle (also sickle due to acidosis, hyperosmolarity)
- ▶ Splenectomies common, can be fatal
- ▶ SS patients have the worst systemic complications while SC and Sthal patients have the most severe ocular problems

Sickle Cell

- ▶ Related to blood viscosity- ? Related to life expectancy
- ▶ Sickle cell retinopathy progresses through five stages



Red Blood Cell

Sickle Cell Stages


- ▶ Stage I :peripheral arteriolar occlusion
- ▶ Stage II:peripheral arterio-venular anastomoses
- ▶ Stage III: Neo
- ▶ Stage IV: Vitreous Heme
- ▶ Stage V: RD

Sickle Cell Retinopathy

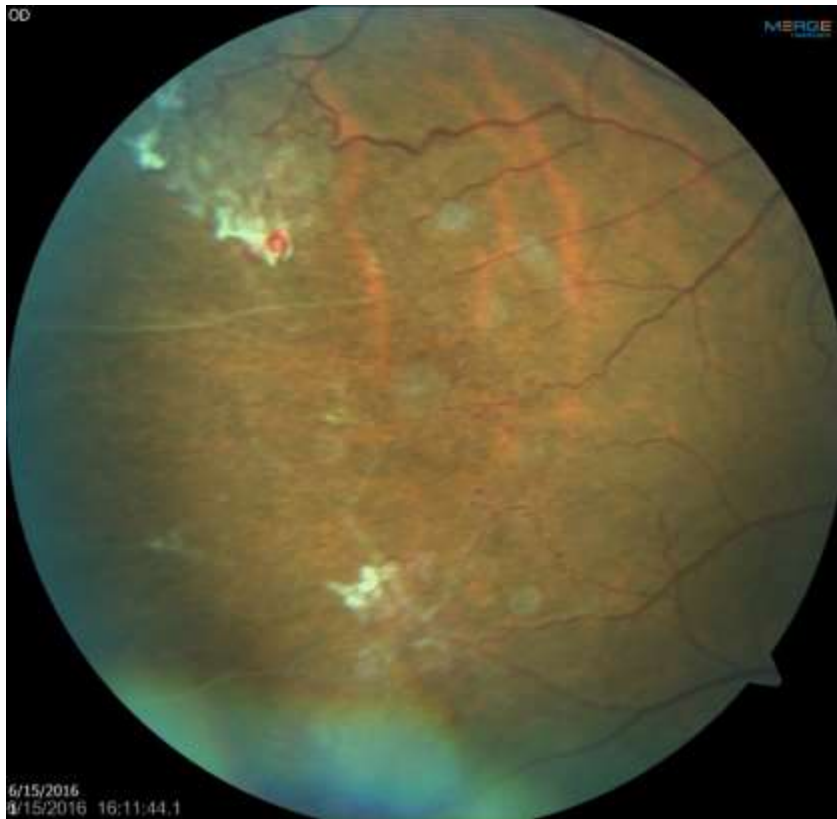
- ▶ Pre-proliferative findings...
- ▶ Salmon-patch hemes
- ▶ Sunburst pigment
- ▶ Refractile bodies
- ▶ Silvering of arterioles
- ▶ ERM
- ▶ Schisis
- ▶ Conj. comma sign
- ▶ Proliferative findings and others:
- ▶ Sea-fan NV
- ▶ Vit Heme
- ▶ RD
- ▶ Angioid streaks
- ▶ CRAO / BRAO
- ▶ Hyphema issues (24-24 rule)

Sickle Cell Retinopathy

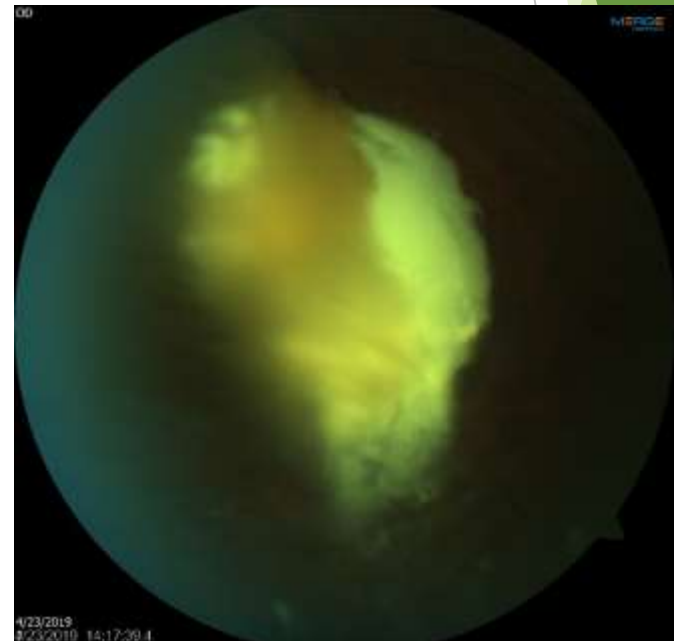

- ▶ PRP or cryo anterior to sea fans
- ▶ Anti-VEGF injections
- ▶ Is treatment always necessary? No! Why not?



Sea fans: S-Thal

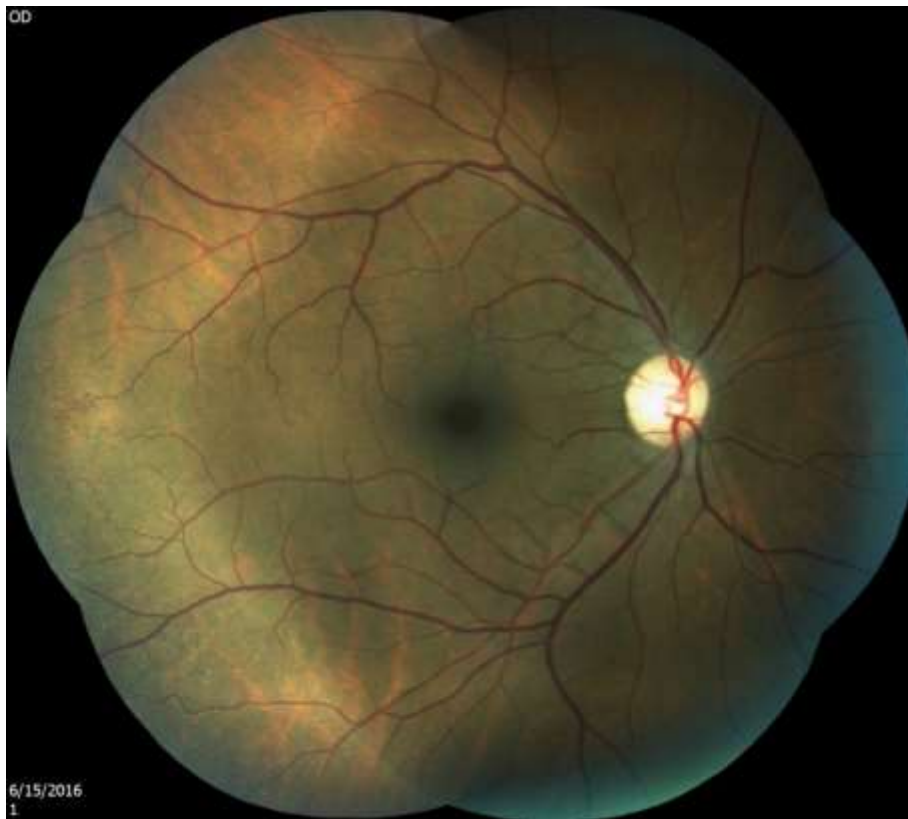


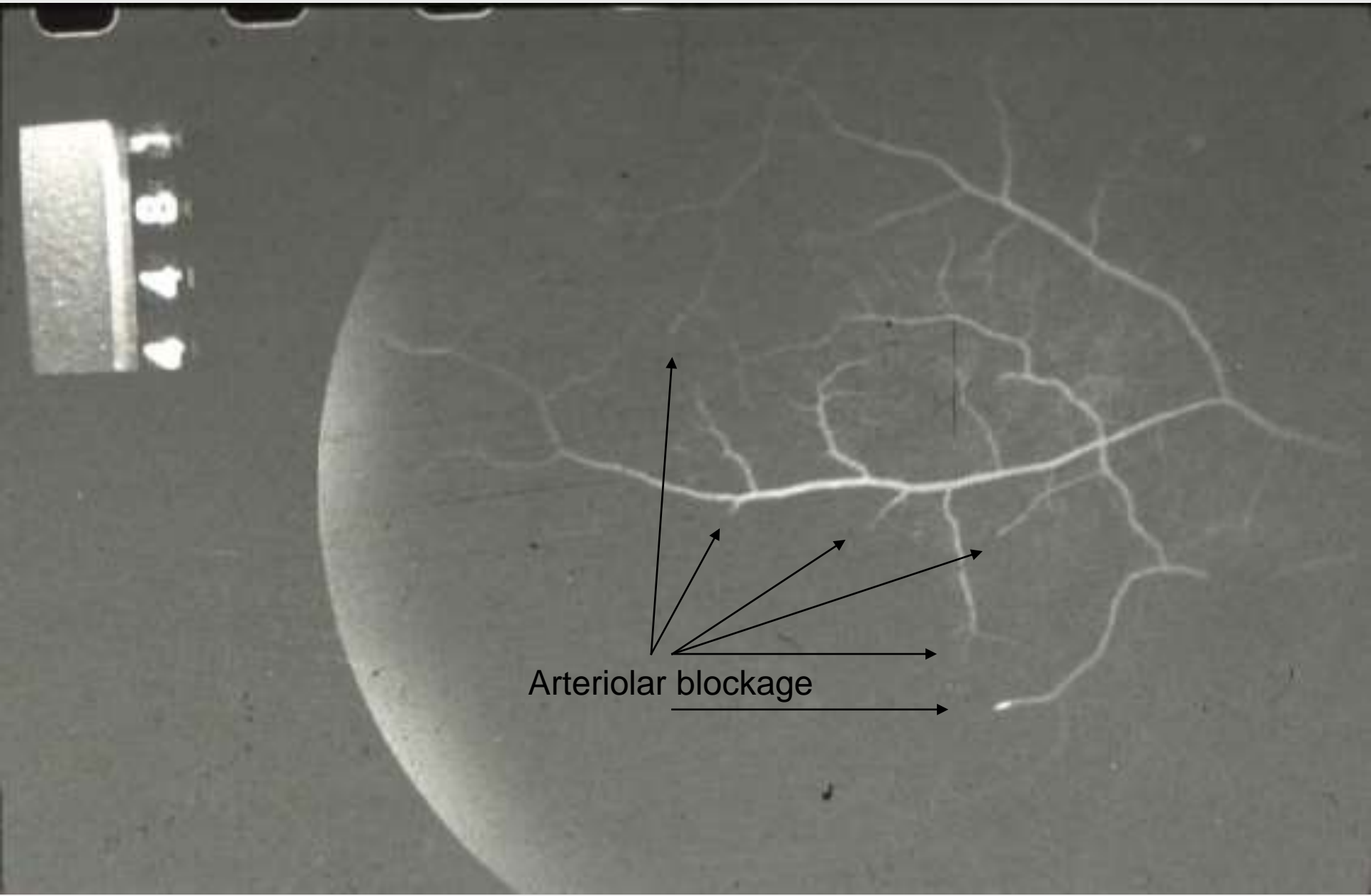
2016



2019

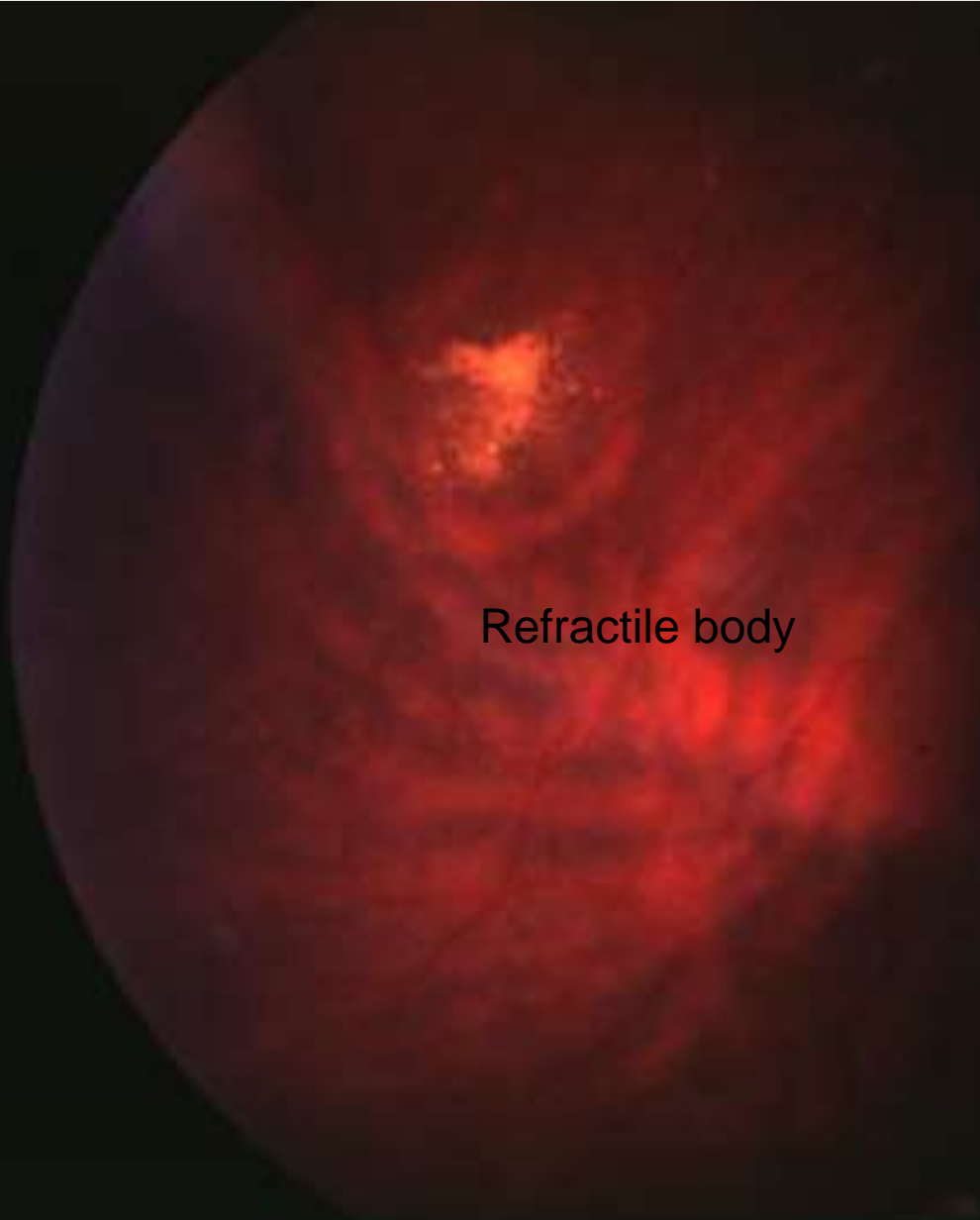
Peripheral anastomoses: S- Thalassemia





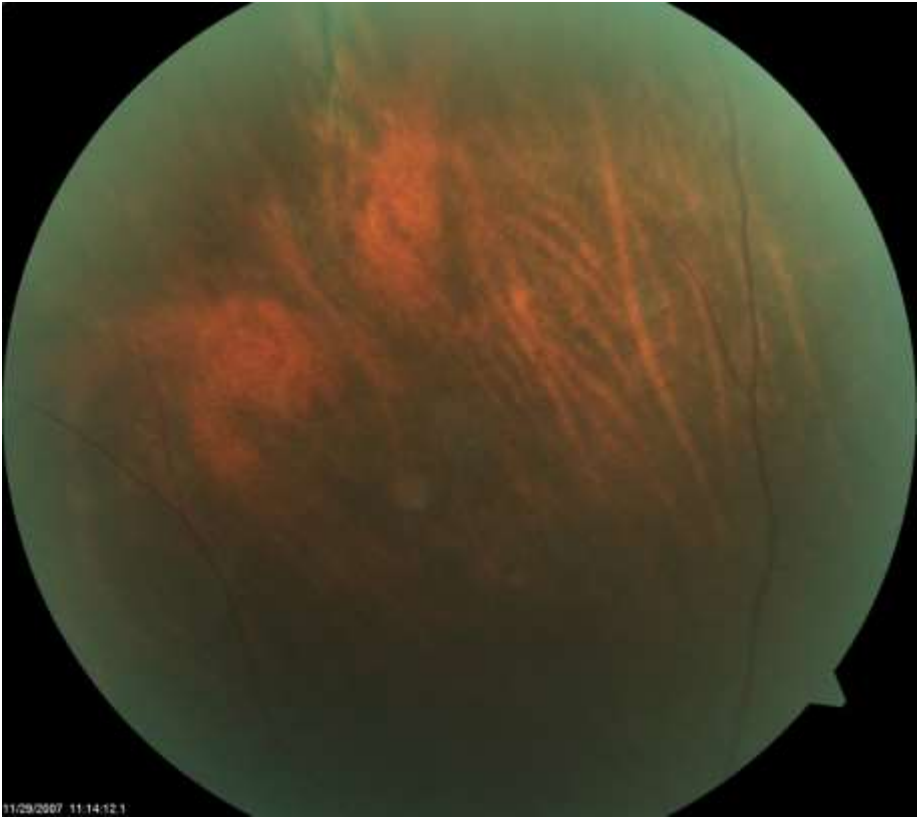
Arteriolar blockage

9 3 0 0 6

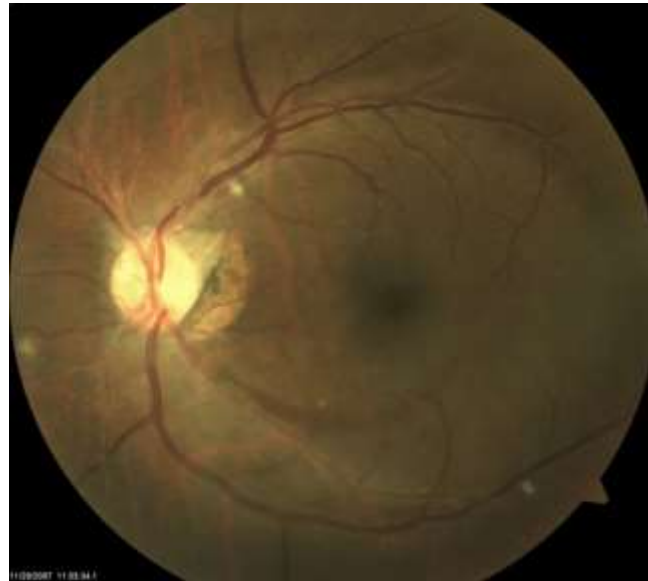
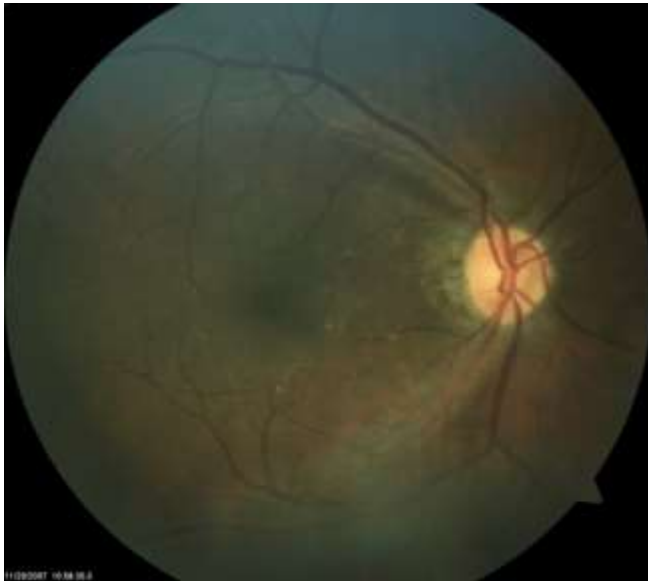
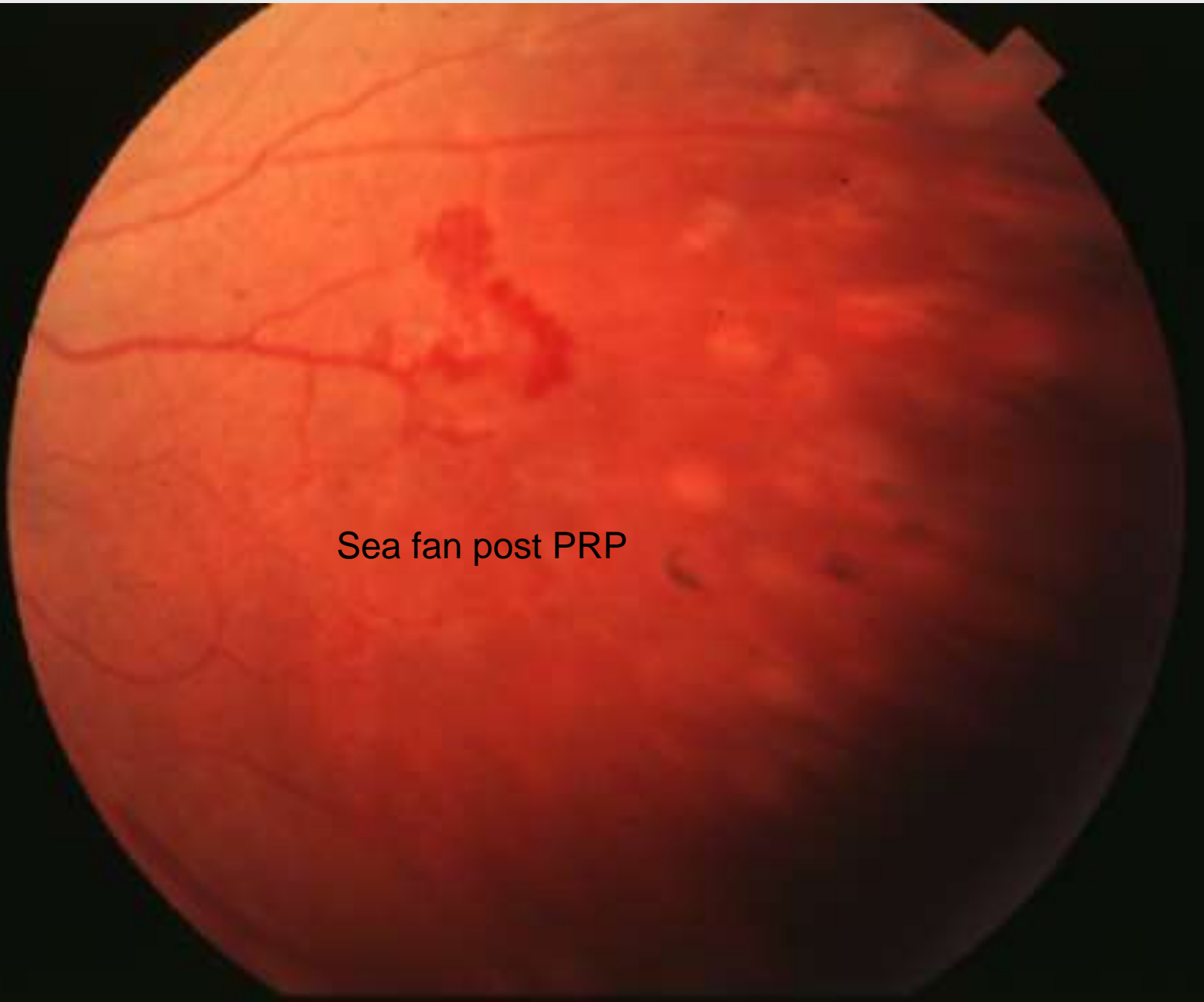
Refractile body

Sunburst pigment



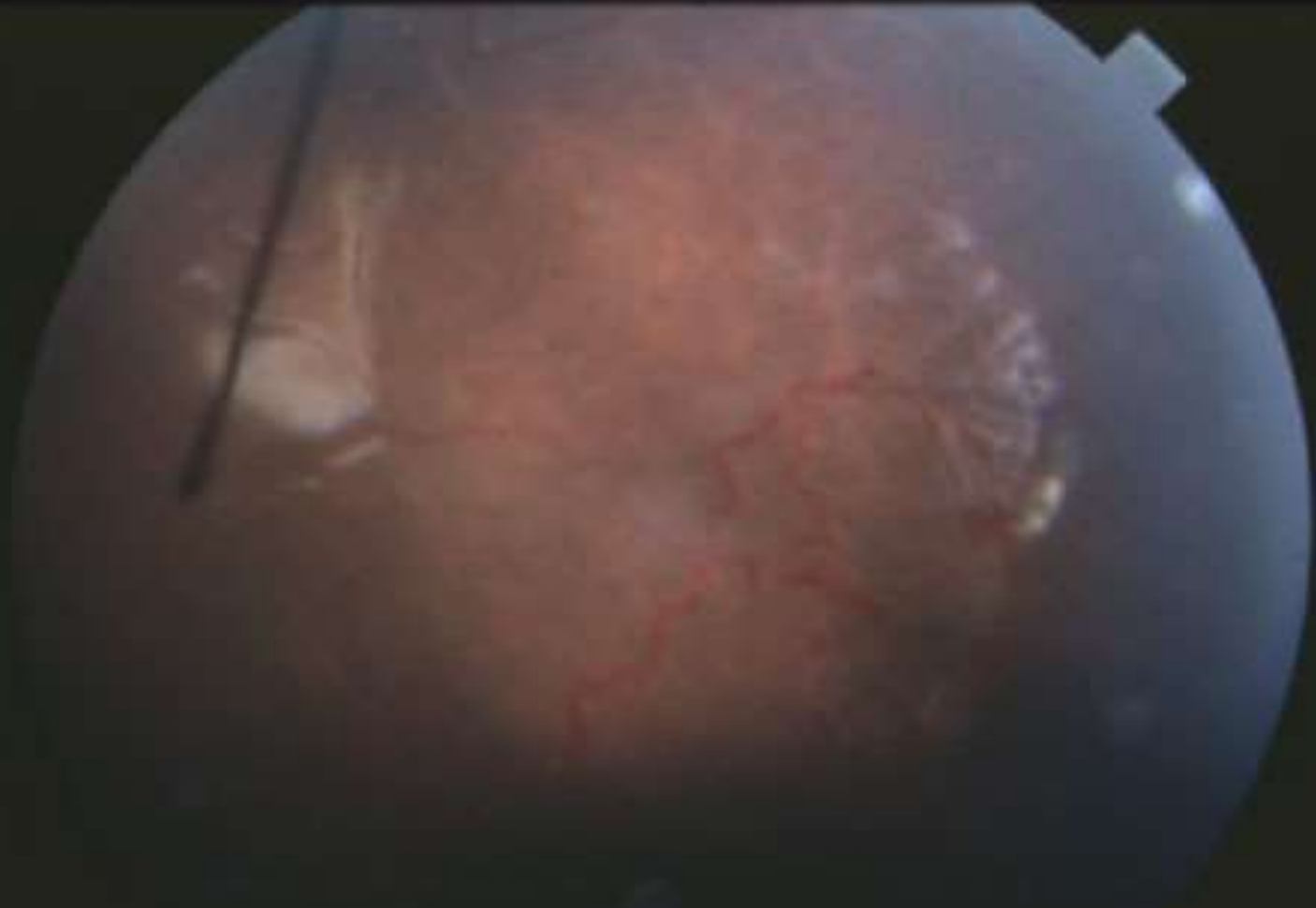Sickle cell with CWS & ERM

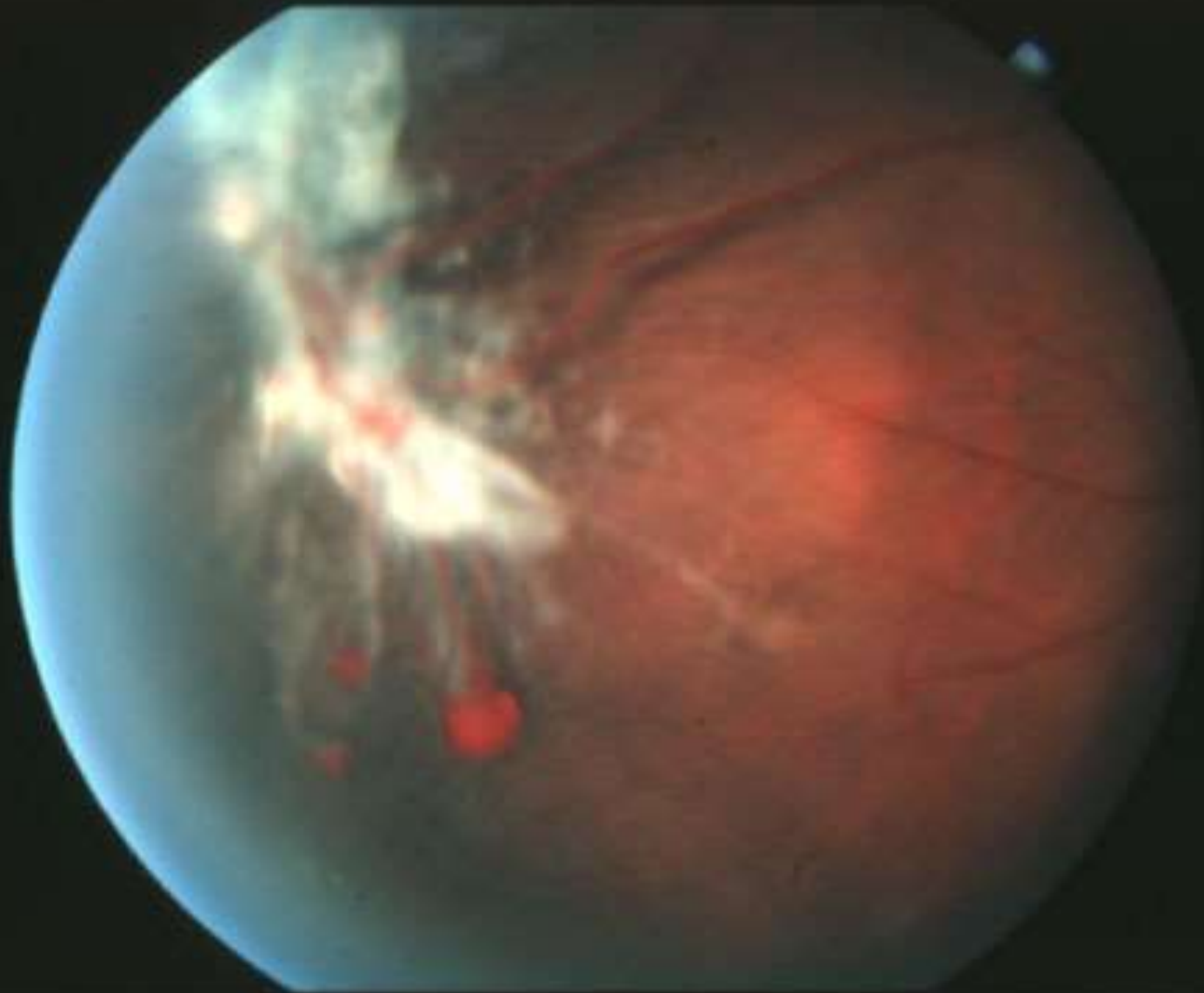




Sea fan post PRP

001.7





Hypertensive Retinopathy

- ▶ 58 million Americans with HTN
- ▶ About 40% of AA adults; around 30% of C adults
- ▶ 75% of people over age 65
- ▶ 20% of all hypertensive individuals are undiagnosed
- ▶ Primary hypertension comprises 85-90% of all cases

Hypertensive Retinopathy

- ▶ Many associated retinal findings-window to the body
- ▶ Arteriosclerosis, or arterial hardening, is an early finding
- ▶ Narrowing of the arteries

Hypertensive Retinopathy Grading

- ▶ Grade I : arteries $\frac{3}{4}$ normal caliber
- ▶ Grade II : arteries $\frac{1}{2}$ normal caliber
- ▶ Grade III : arteries $\frac{1}{3}$ normal caliber
- ▶ Grade IV : arteries thread-like or invisible

Study

- ▶ *Hypertension* Journal 2013 (October issue)
- ▶ 2907 Hypertensive patients followed for 13 years.....
- ▶ Mild HTN retinopathy = 35% increase in stroke risk
- ▶ Moderate to severe HTN retinopathy = 137% increase in stroke risk

Hypertensive Retinopathy

- ▶ Sclerosis > increased ALR
- ▶ Flame hemes (NFL)
- ▶ CWS (diastolic above 110)
- ▶ Gunn's sign
- ▶ Papilledema
- ▶ Vein occlusions



Malignant Hypertension

- ▶ Ocular findings are severe and include exudative edema and papilledema
- ▶ Mortality rate:
 - ▶ 80% @ 1 year
 - ▶ 95% @ 2 years



Hypertensive Retinopathy

- ▶ The choroid is commonly affected
- ▶ Elschnig's spots and Siegrist's streaks
- ▶ Watch asymmetry: possible carotid issues

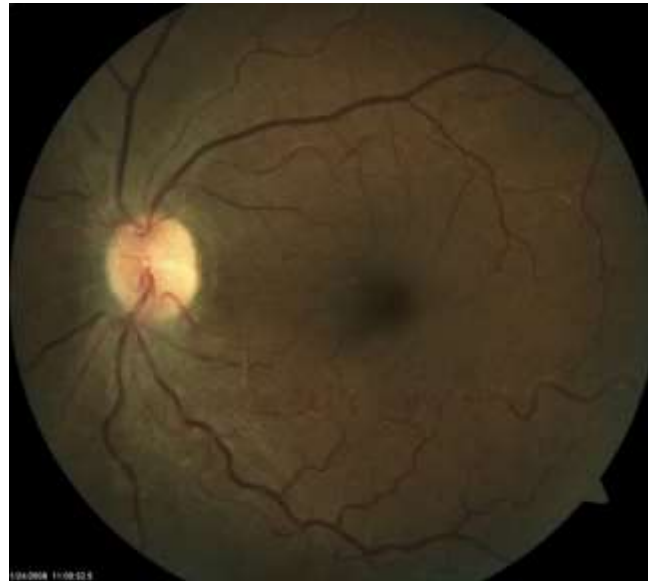
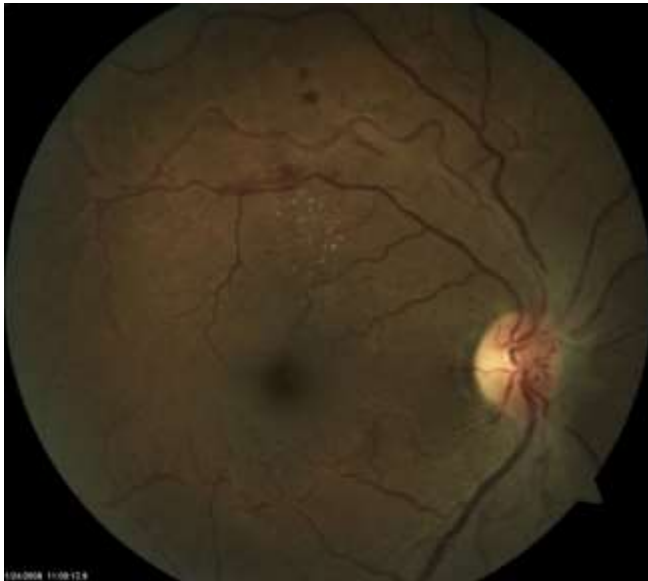

Hypertensive Retinopathy

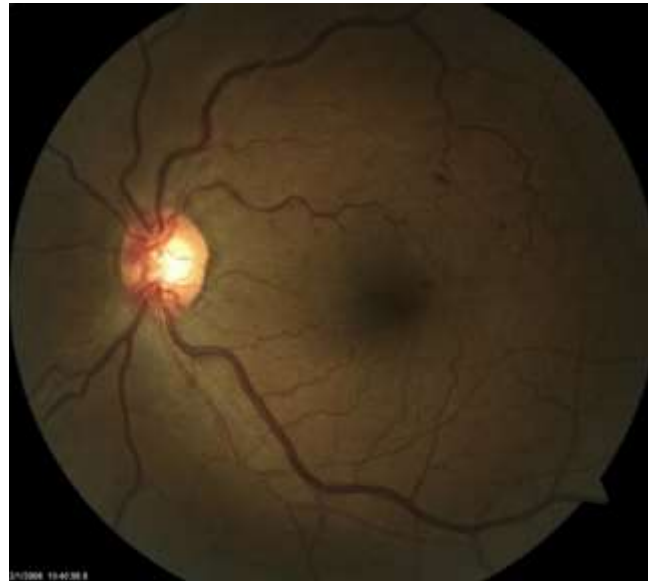
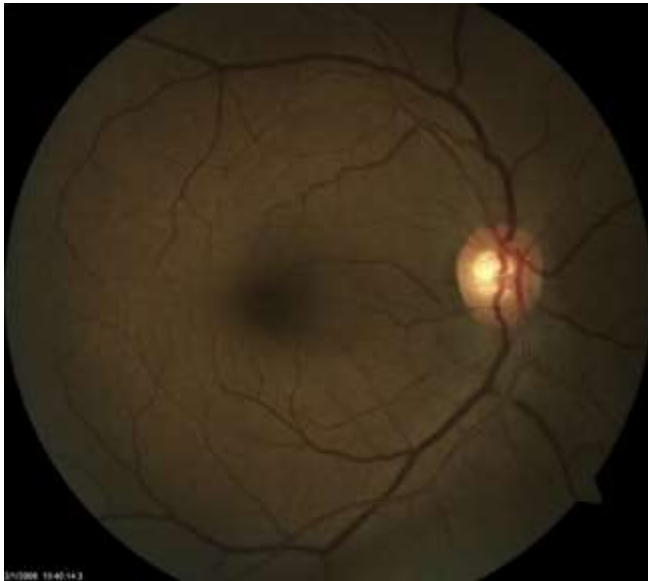
- ▶ No ocular treatment; manage by controlling systemic disease



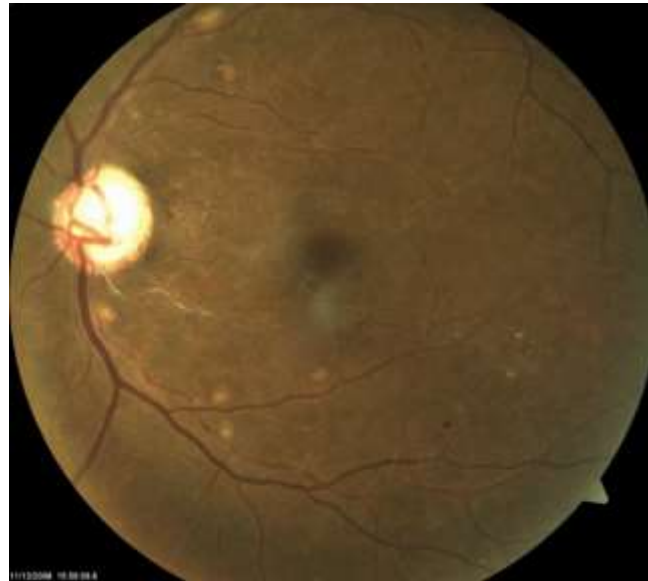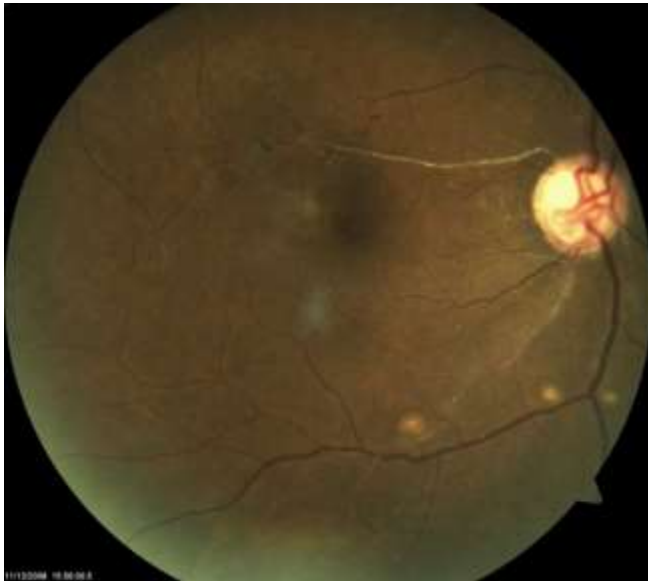HTN vasculopathy



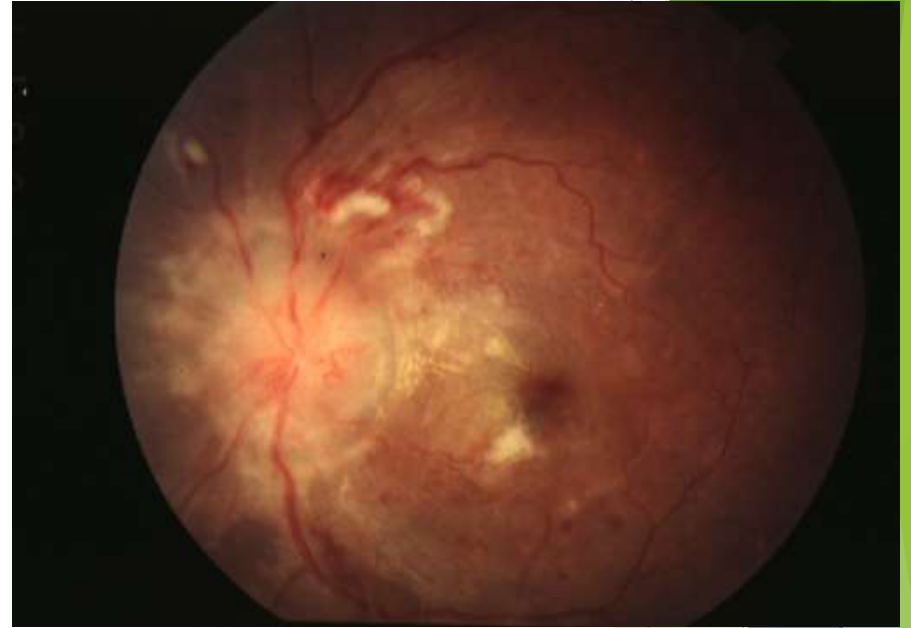
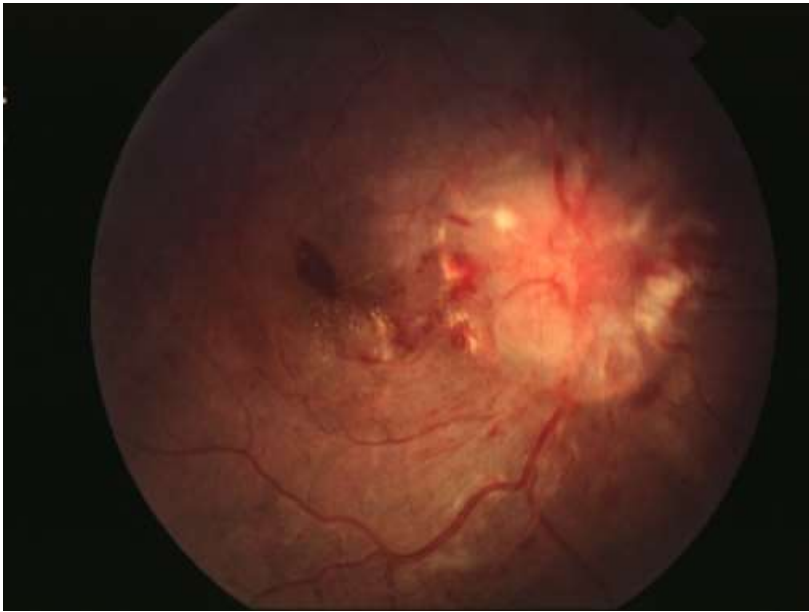HTN vasculopathy and BRVO



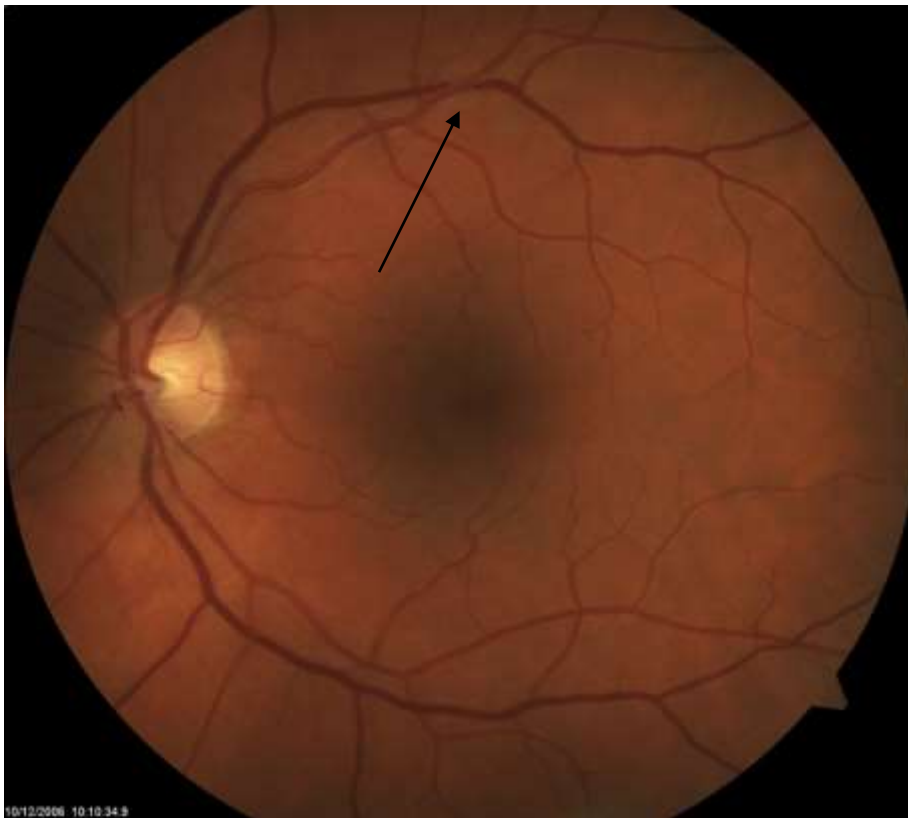
HTN vasculopathy



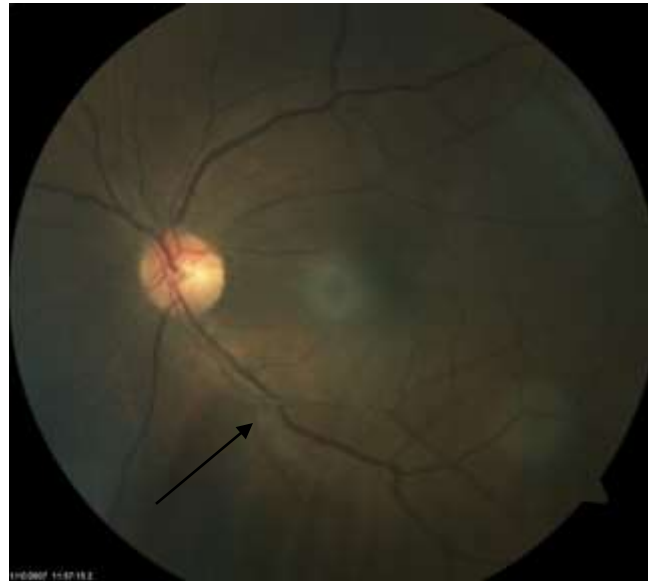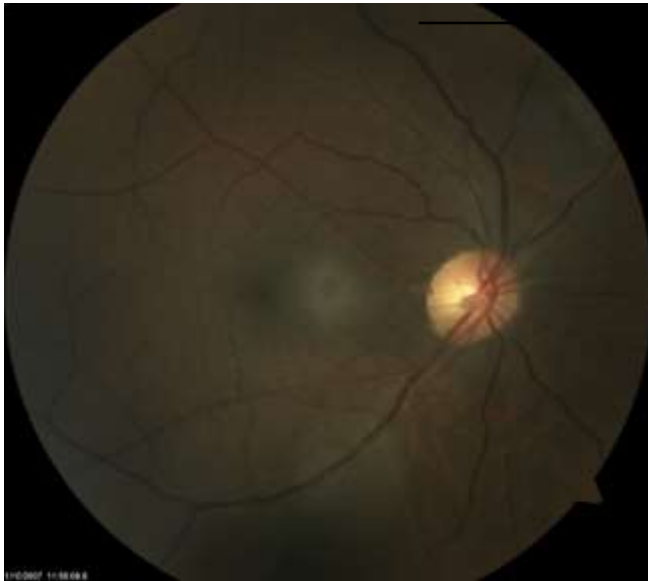Malignant HTN papilledema



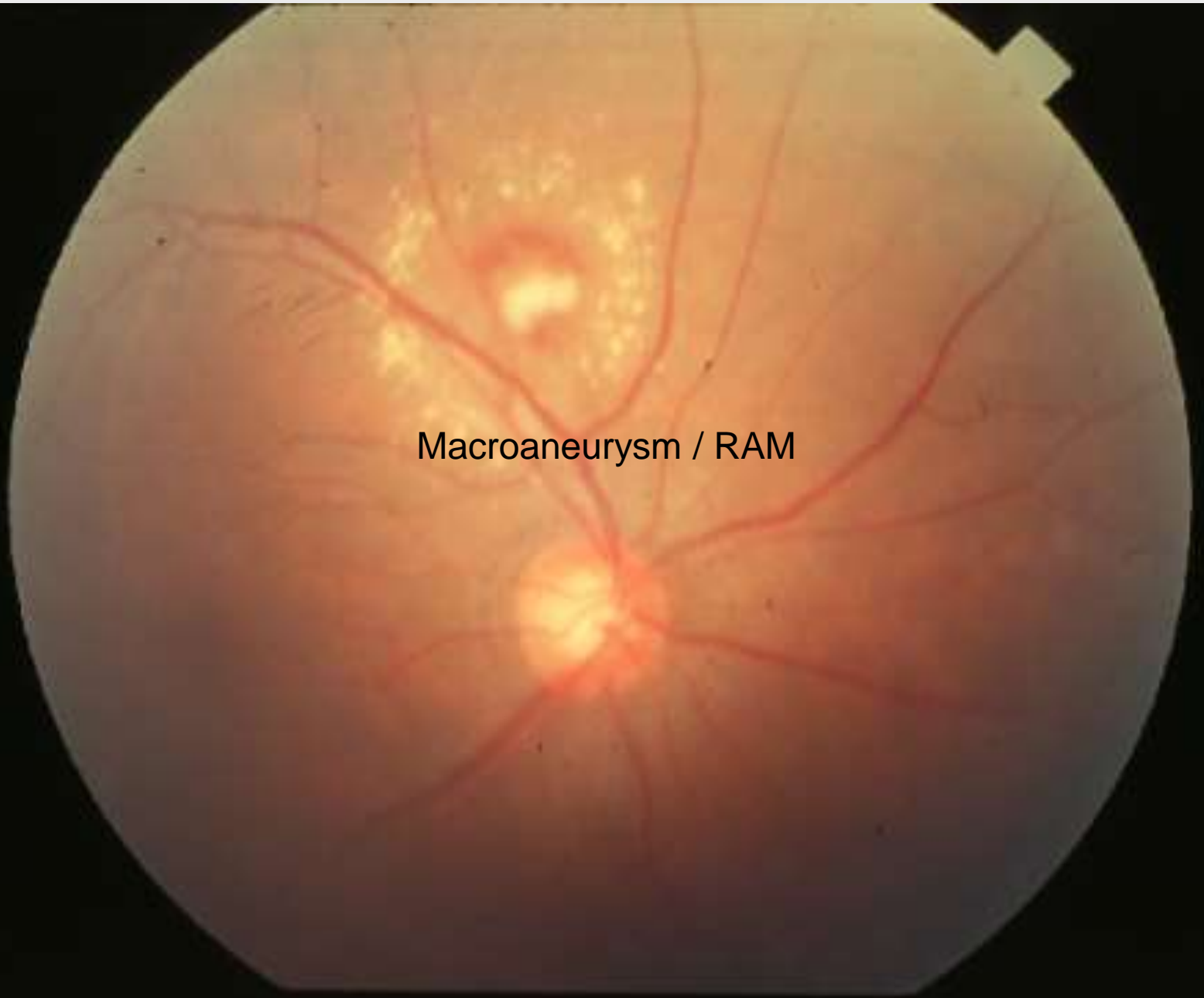
Crossing Change (Gunn's sign)



Crossing changes

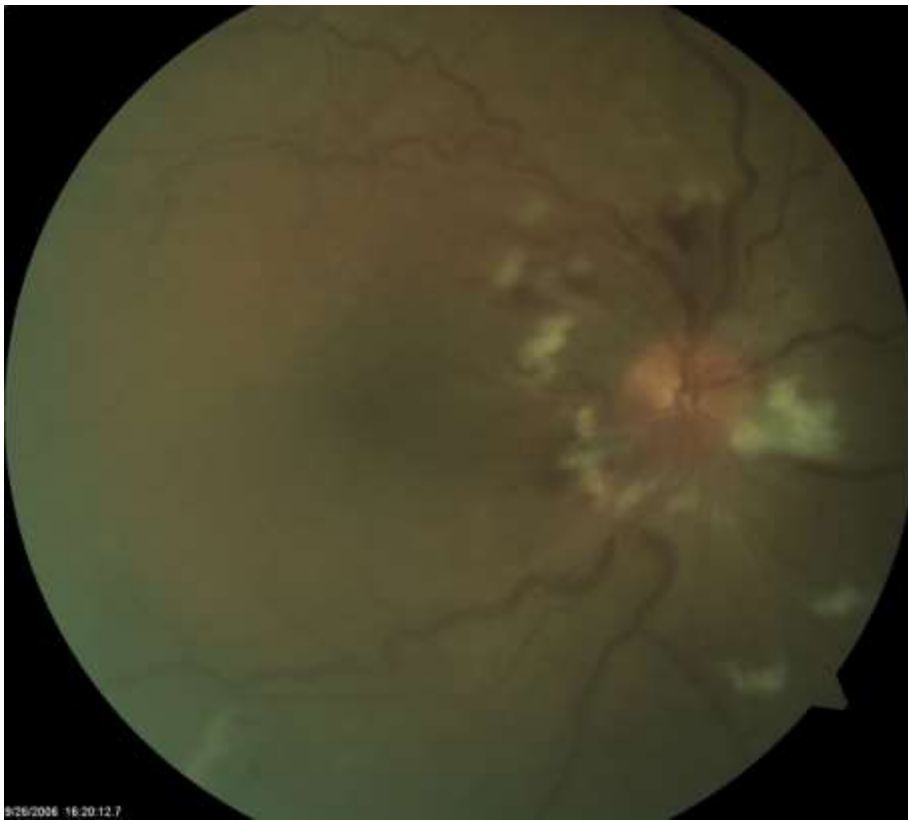

0.0.0.5

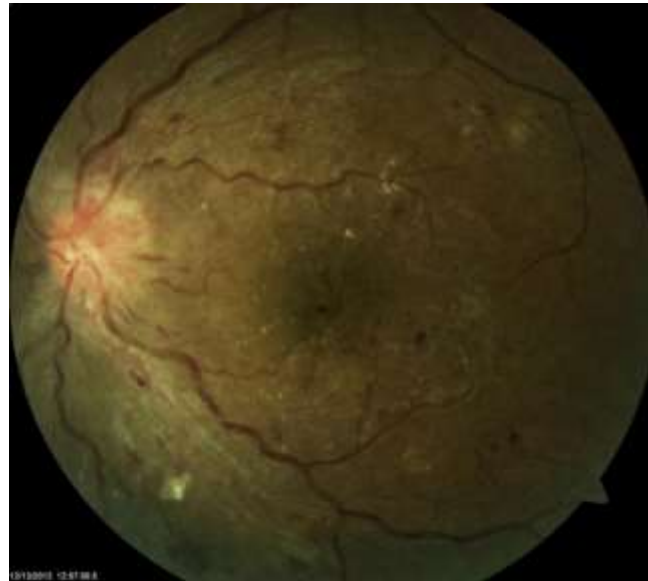
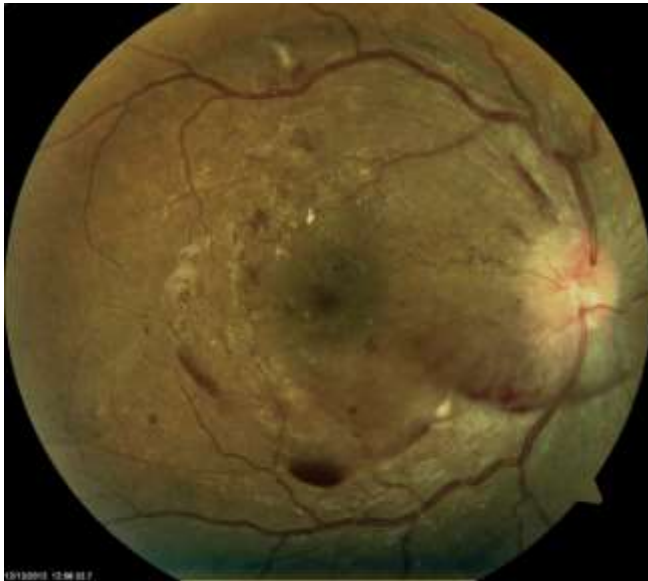
Macroaneurysm / RAM

HTN retinopathy



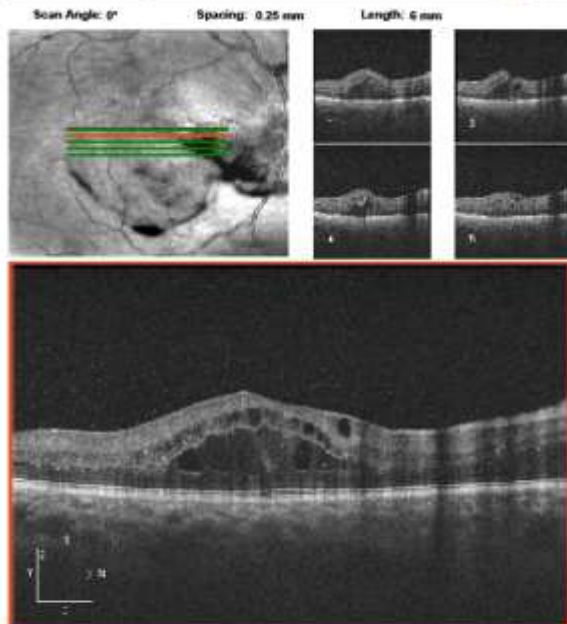
HTN Retinopathy BP 240 / 135



BP 240/135

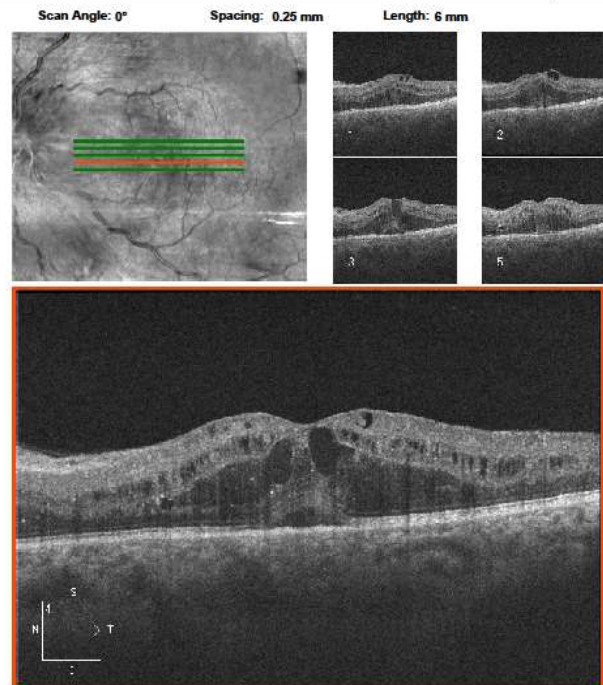
High Definition Images: HD 5 Line Raster

OD OS



High Definition Images: HD 5 Line Raster

OD OS



Bp 240 / 135

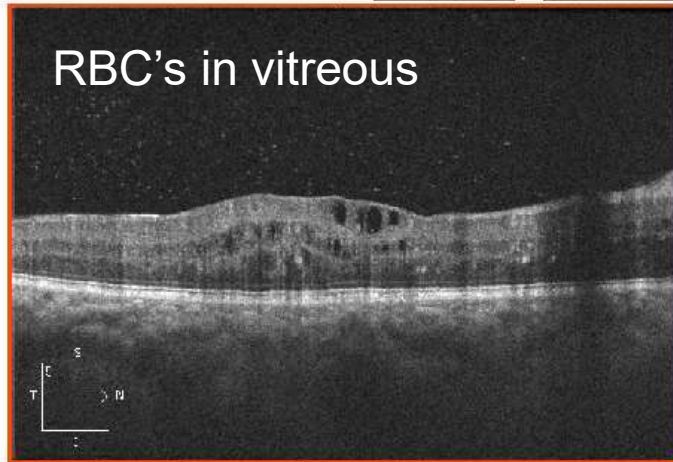
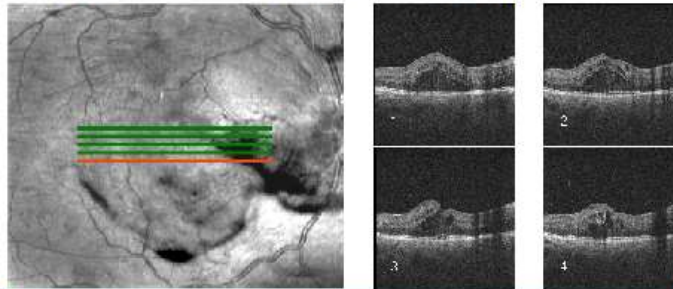
High Definition Images: HD 5 Line Raster

OD OS

Scan Angle: 0°

Spacing: 0.25 mm

Length: 6 mm

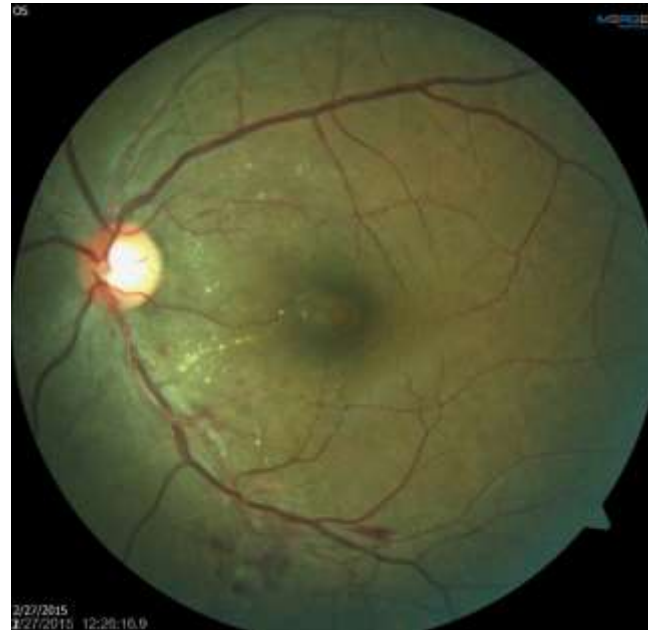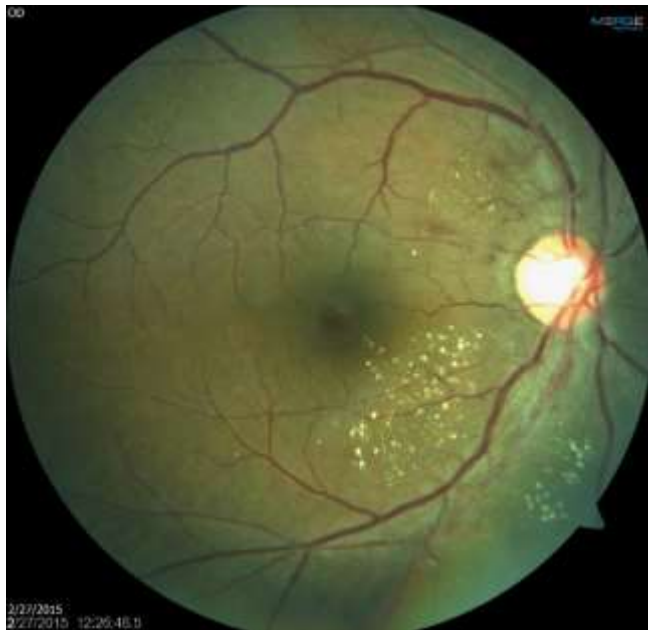


Comments
Acquired using enhanced depth mode

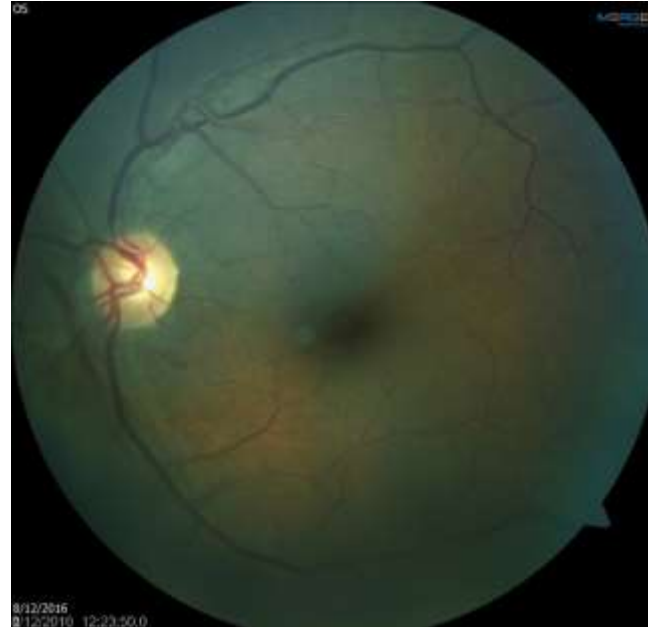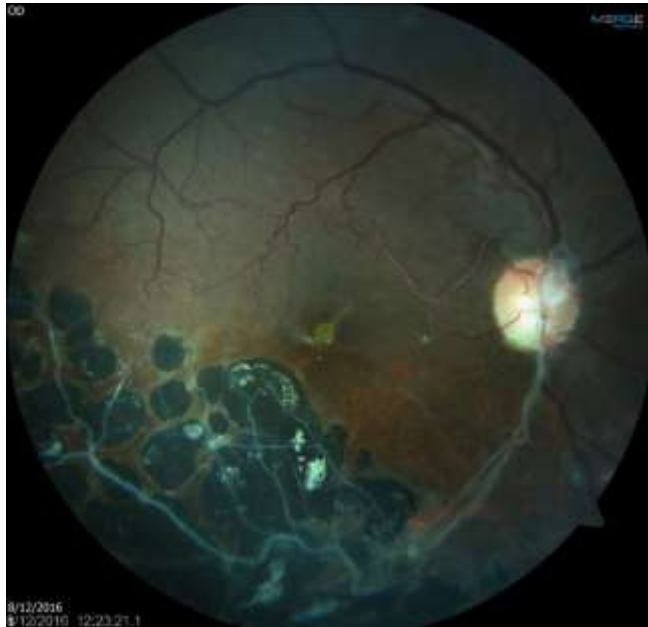Doctor's Signature

SW Ver: 6.0.1.24
Copyright 2012
Carl Zeiss Meditec, Inc
All Rights Reserved
Page 1 of 1

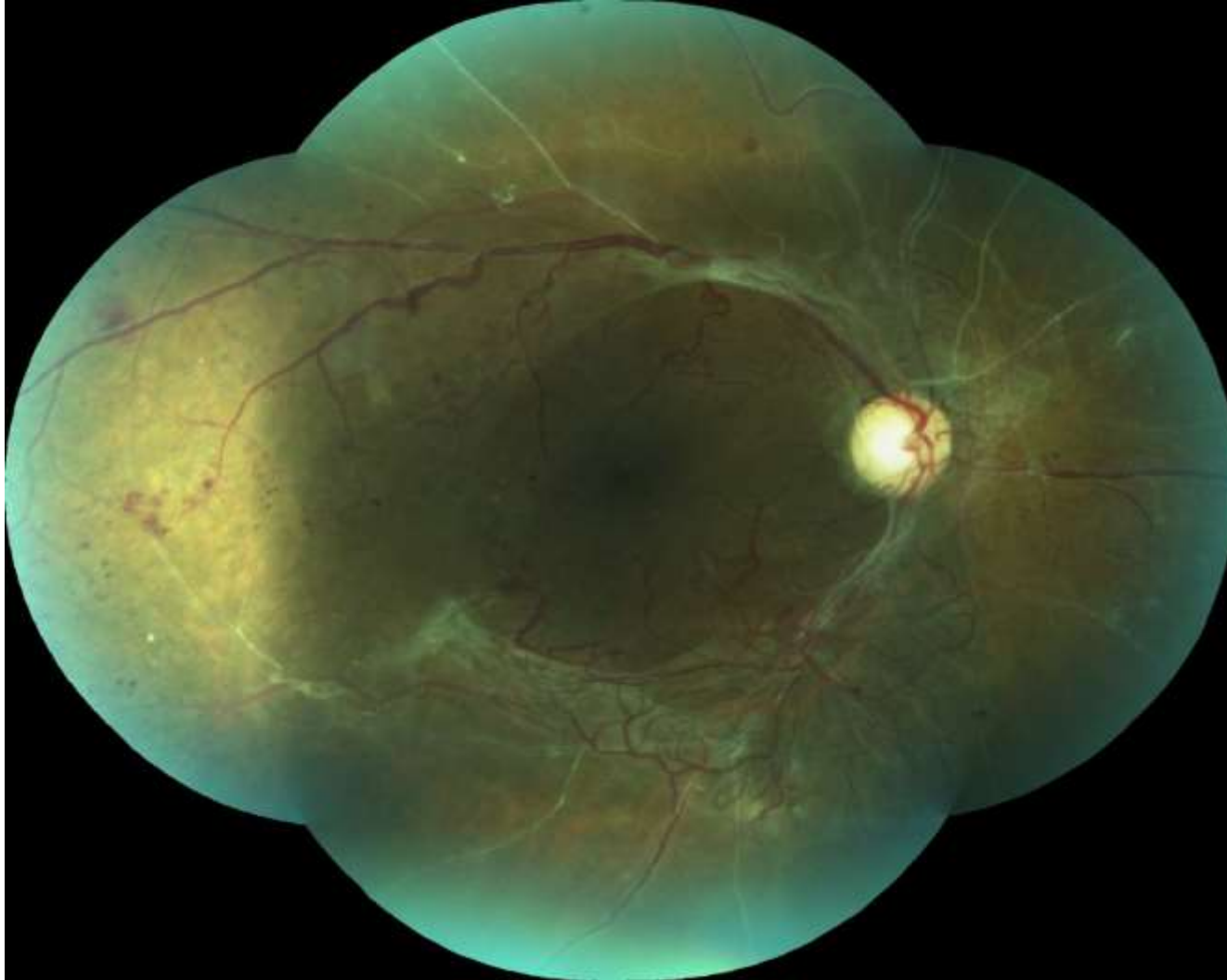HTN retinopathy 20/20 OU



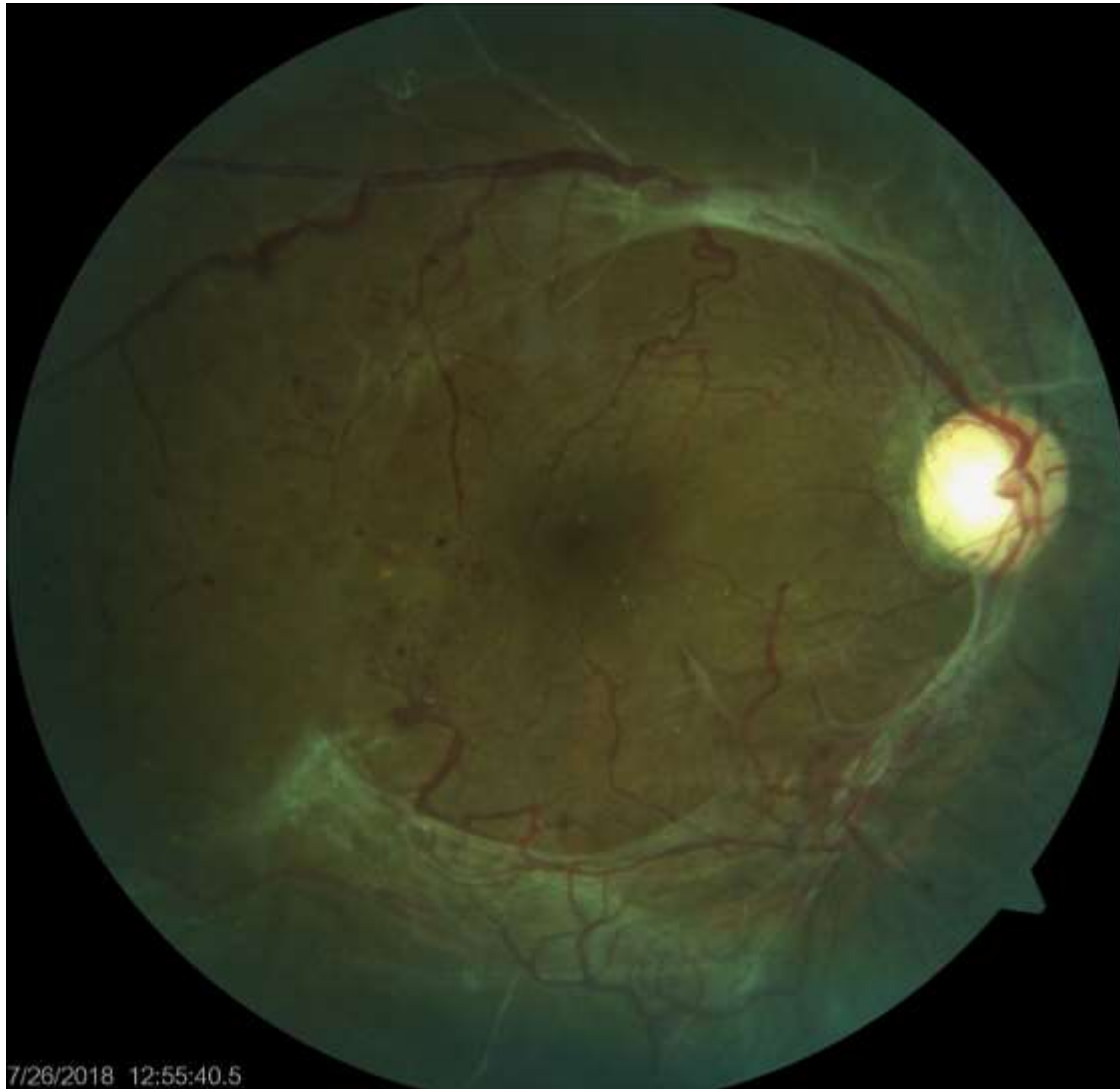HTN vasculopathy



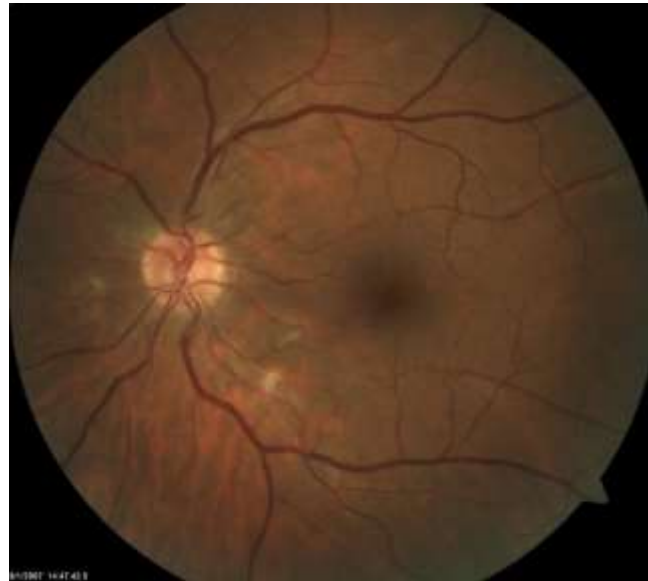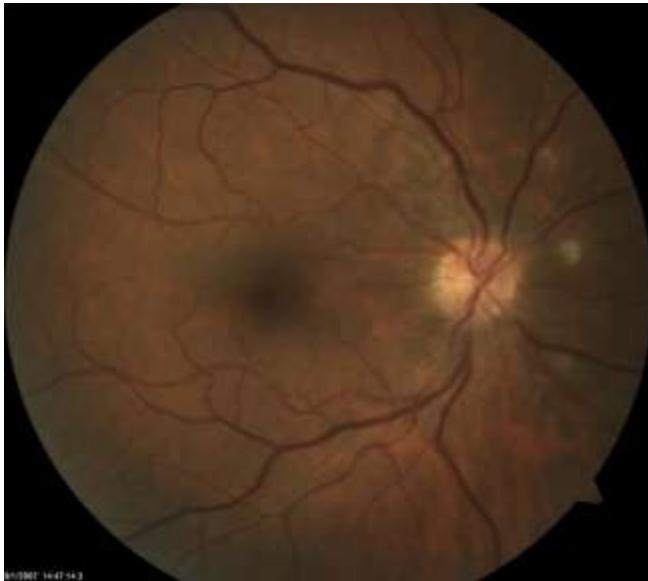HTN vasculopathy and PDR



HTN vasculopathy and PDR



CWS S/P MI with angioplasty



Eale's Disease

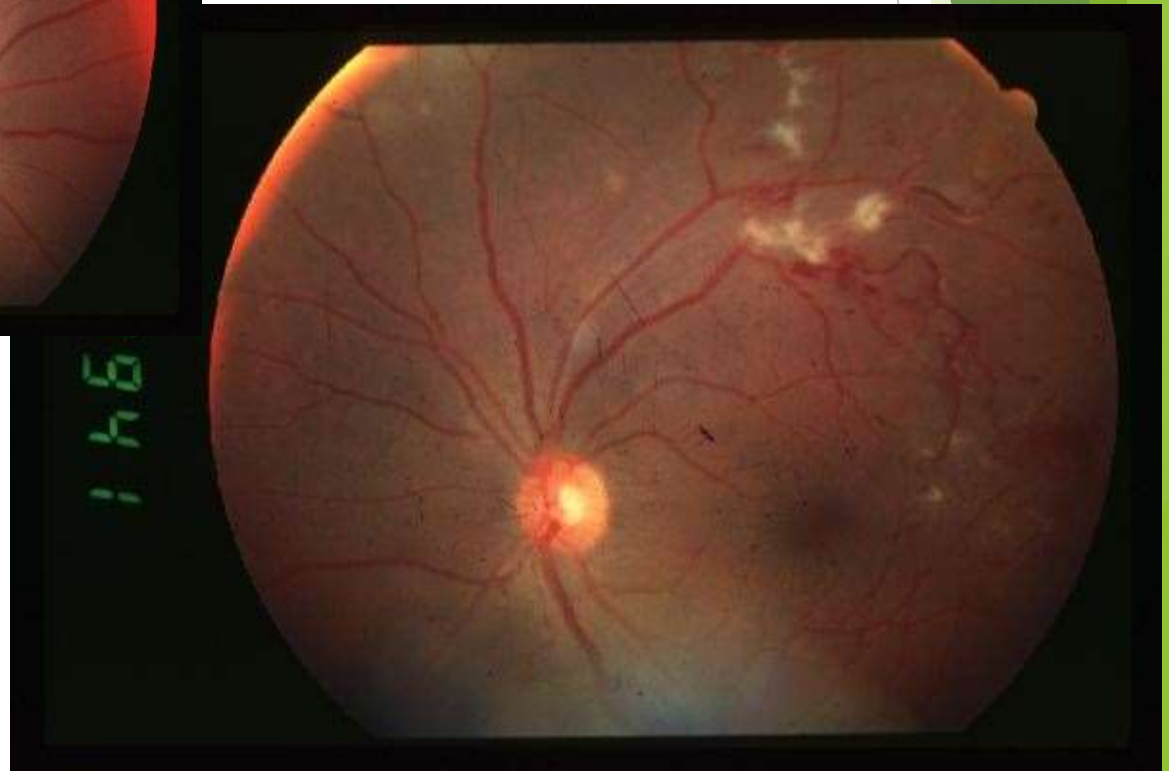
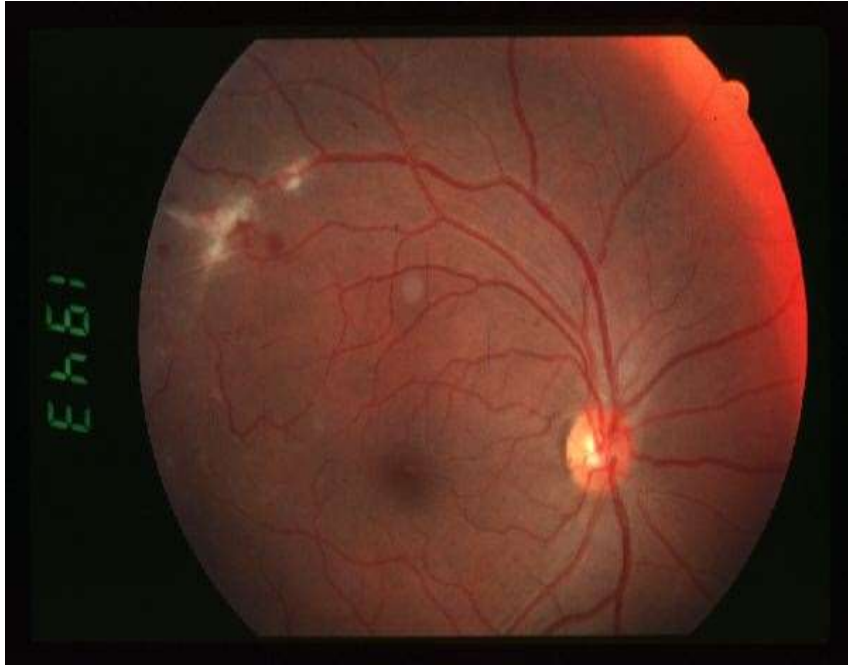
- ▶ Idiopathic vasculopathy affecting healthy, young adults. India, Pakistan, and Afghanistan
- ▶ Usually strikes patients in their twenties or thirties. M>F ? TB protein



Eale's Disease

- ▶ Retinal vascular sheathing and exudative sheathing in the periphery
- ▶ CME, vitreal cells, anterior chamber cells/flare, and peripheral retinal non-perfusion
- ▶ Neovascularization of the retina, disc, and iris are possible
- ▶ Treatment consists of PRP + / - anti VEGF

Eale's disease



Coat's Disease

- ▶ Idiopathic retinal condition consisting of telangiectatic and aneurysmal vessels with significant exudation
- ▶ Adolescent and adult forms
- ▶ Males 3x females ; 80-95% unilateral
- ▶ Leukocoria, poor vision, strabismus
- ▶ * What are the other main causes of leukocoria in children?

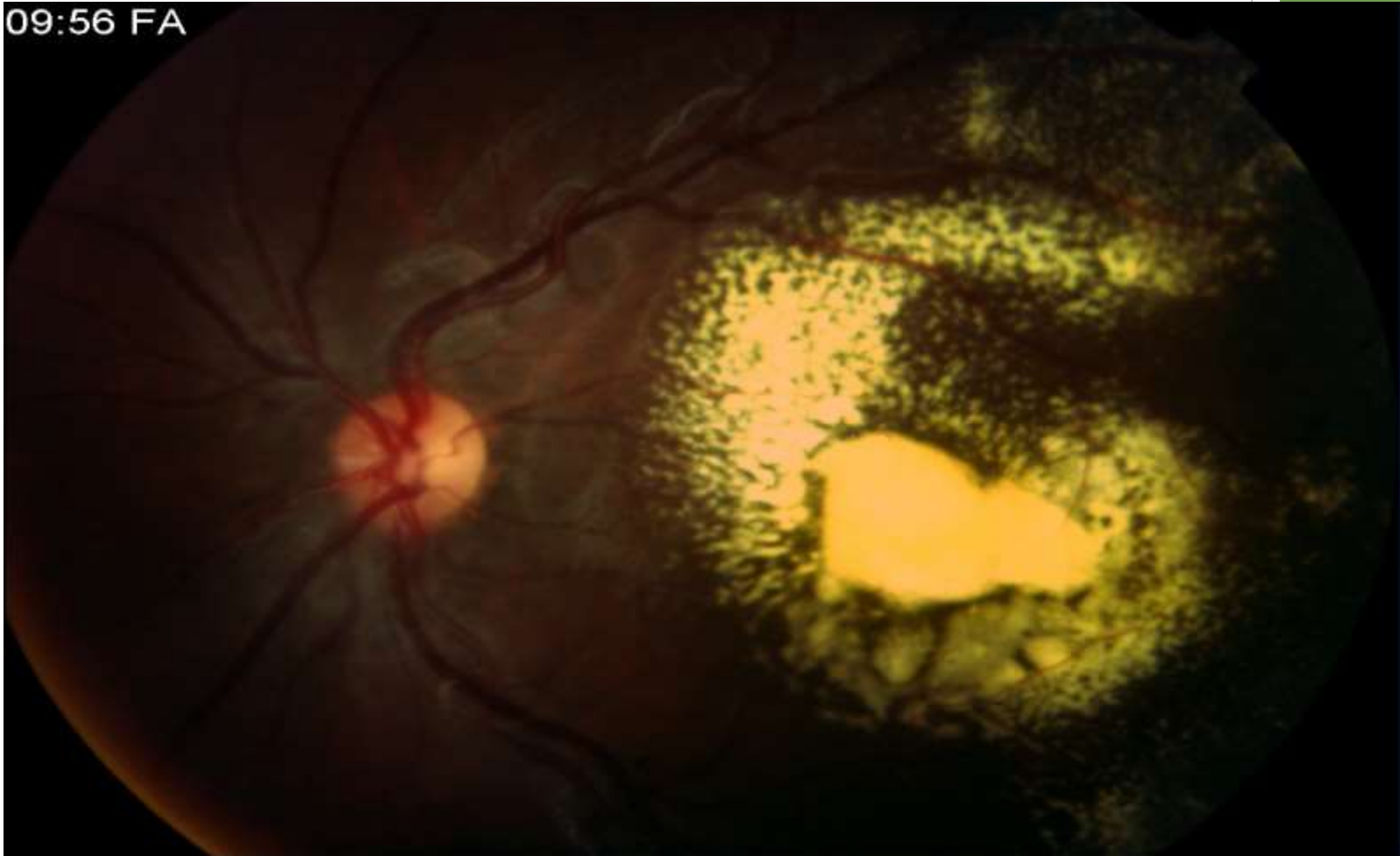Coat's Disease



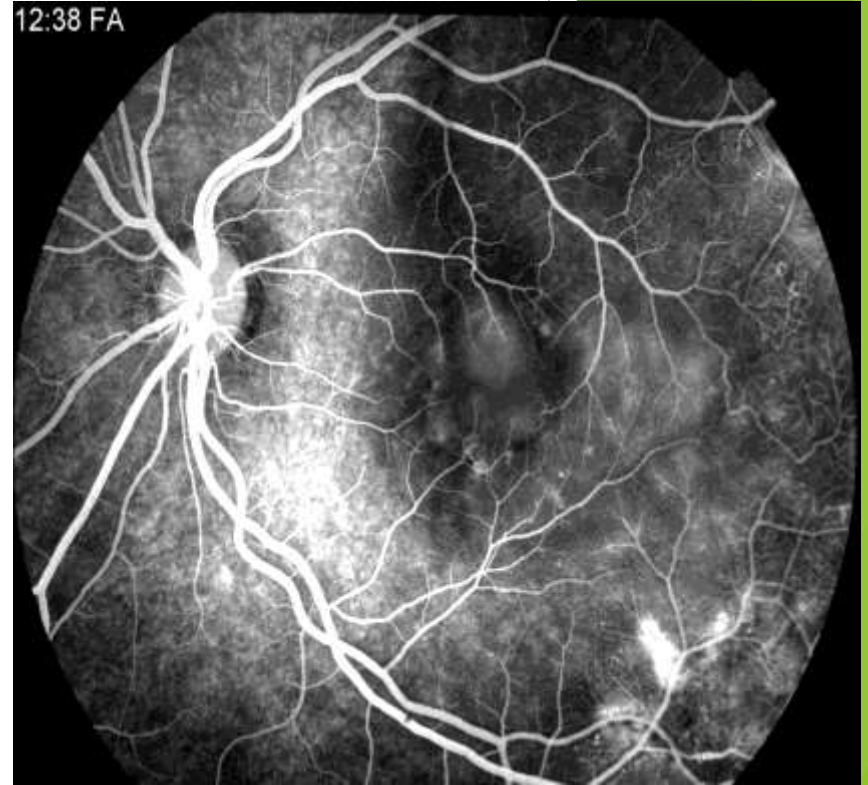
- ▶ Cholesterol issues in adult cases
- ▶ Clinical picture variable
- ▶ IVFA / OCTA most helpful tool in making diagnosis
- ▶ Progressive with exacerbations and remissions
- ▶ Tx with photocoagulation, possibly combined with anti-VEGF or kenalog

Coat's disease (images courtesy Dr. Dan Neely)

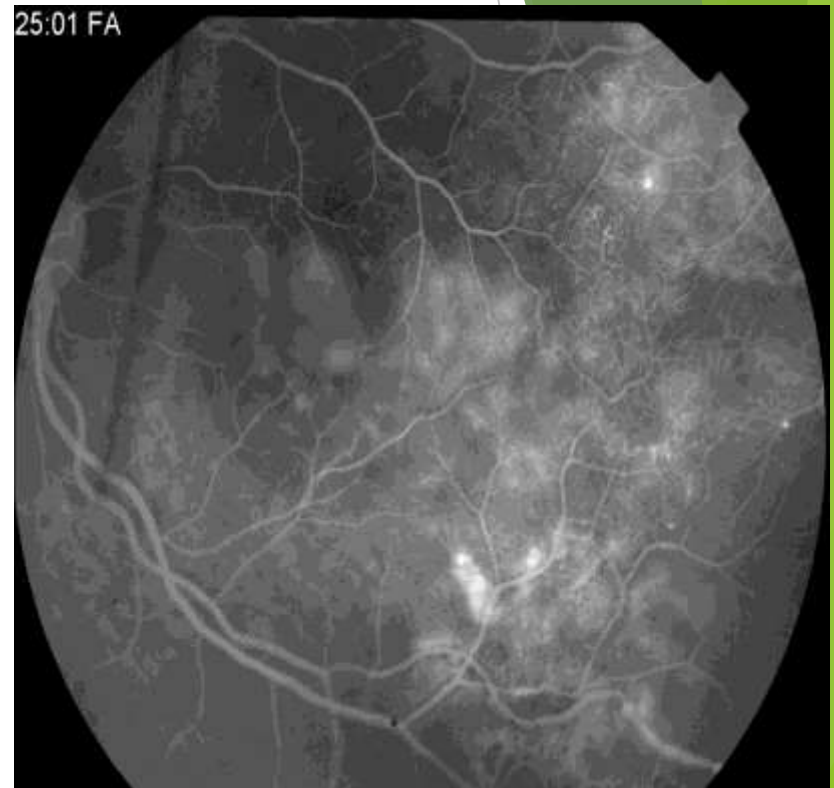09:56 FA



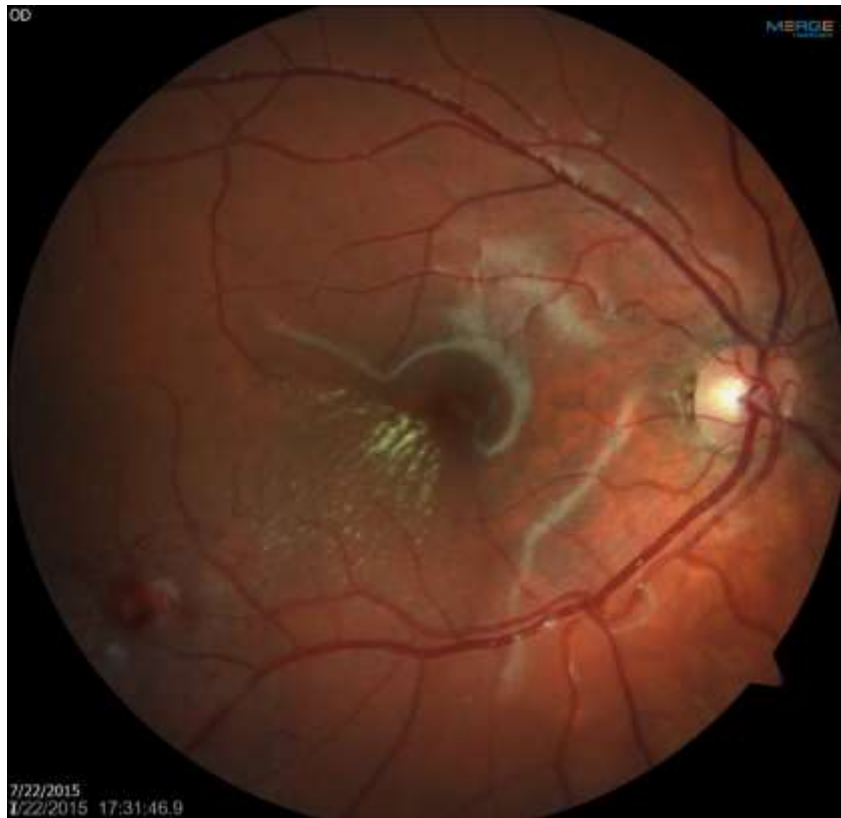Coat's IVFA



Coat's IVFA

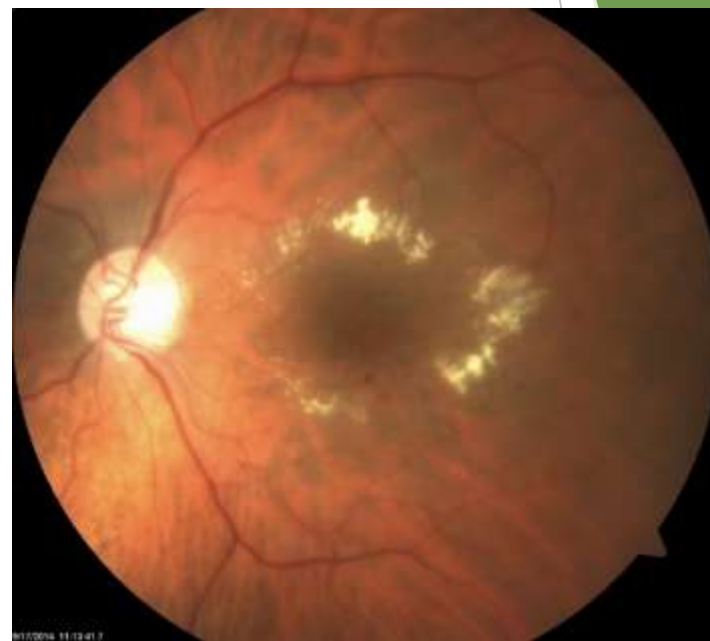


Coat's disease

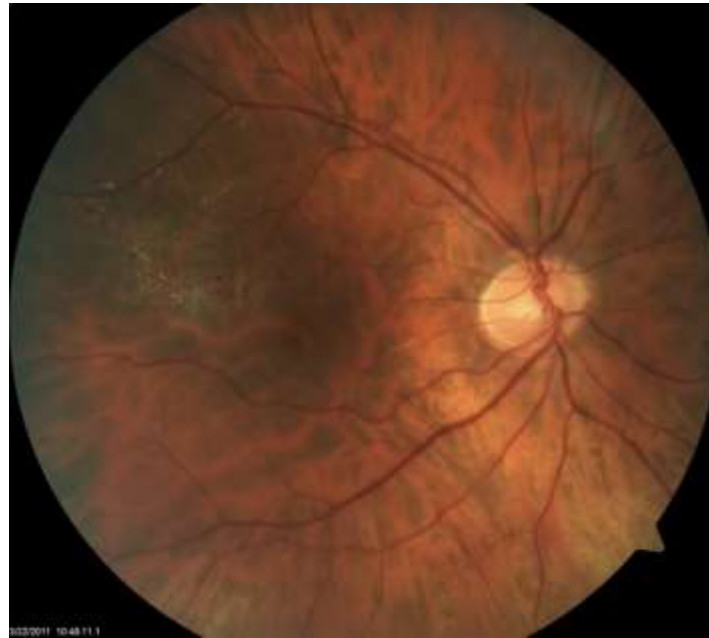

Macular Telangiectasia Type I

- ▶ Unilateral
- ▶ Mostly males, no racial predilection
- ▶ Mean onset 40 years old
- ▶ Prominent, visible telangiectatic capillaries
- ▶ Capillary drop out on OCTA
- ▶ Lipid exudation
- ▶ Macular edema
- ▶ Exacerbations and remissions
- ▶ IVFA, OCT / OCTA to confirm exudative edema
- ▶ Treat with laser photocoagulation, +/- anti VEGF or steroids



Macular Telangiectasia Type I

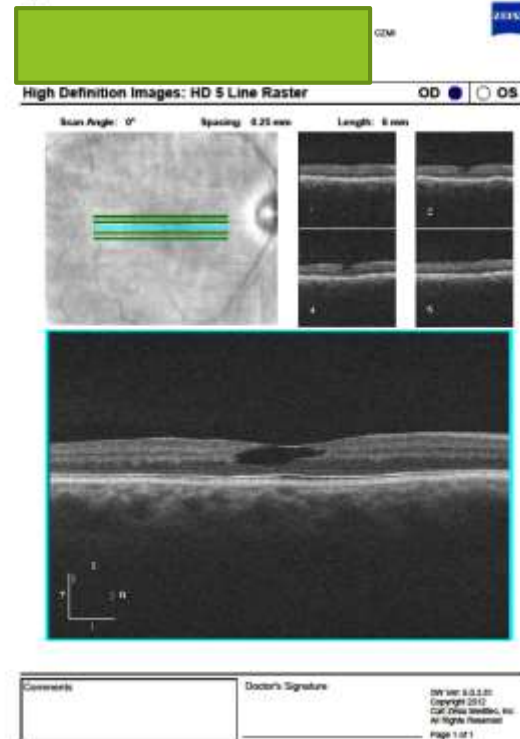
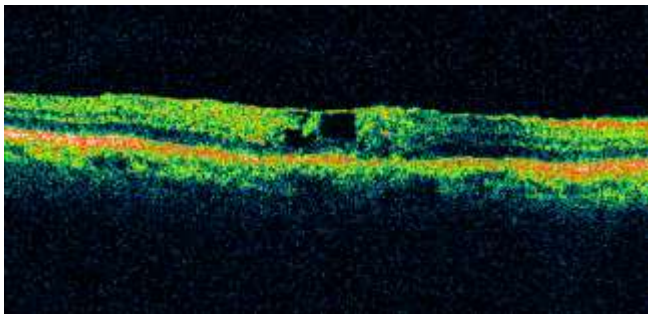


Macular Telangiectasia Type II

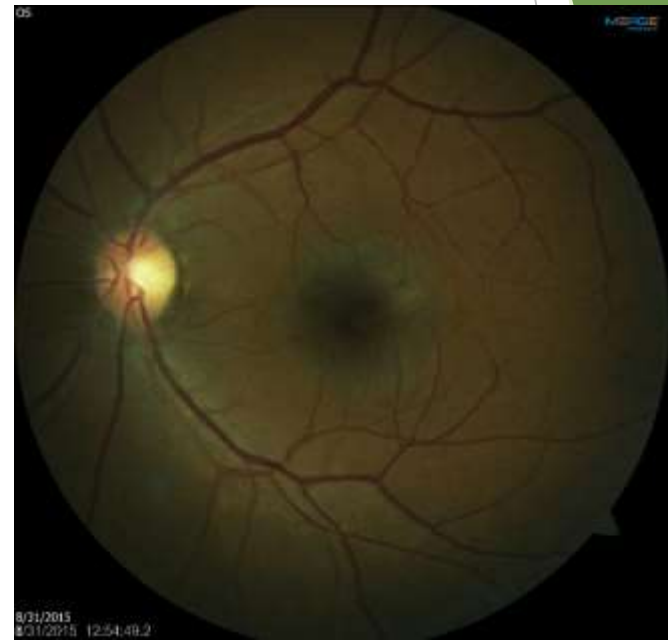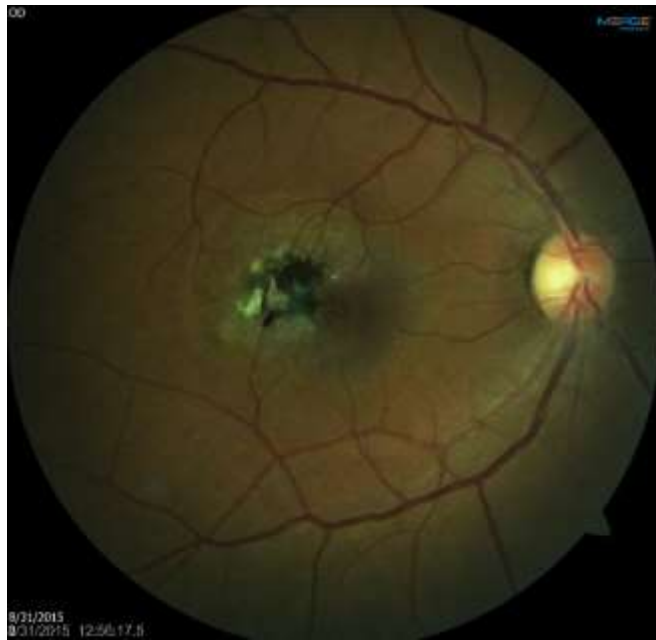
- ▶ No gender or racial predilection
- ▶ Mean age of onset 55 years old, bilateral
- ▶ Mueller cell depletion
- ▶ Little to no exudation
- ▶ Parafoveal graying of the retina, parafoveal telangiectasias, crystalline deposits, macular edema
- ▶ Two subtypes: proliferative (1/3) and non-proliferative (2/3)
- ▶ Proliferative develop SRNVM and subsequent scarring
- ▶ Limited treatment options for non-proliferative
- ▶ Anti-VEGF for proliferative

ILM Drape in Mac Tel II

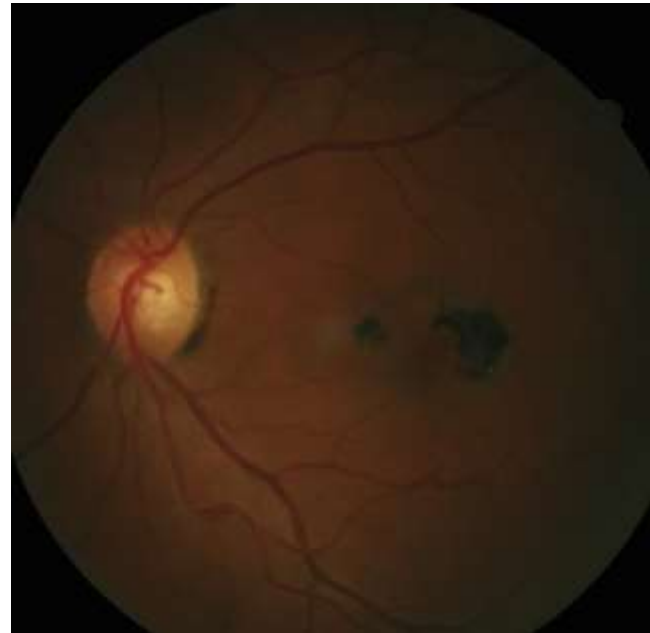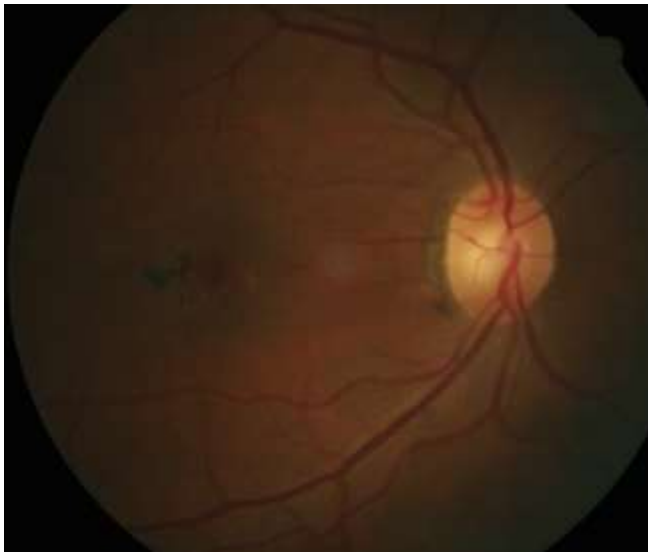Also get right angle vessels in IVFA



Macular telangiectasia Type II



Macular Telangiectasia Type II (courtesy Dr. Diana Schechtman)



Macular Telangiectasia Type

III

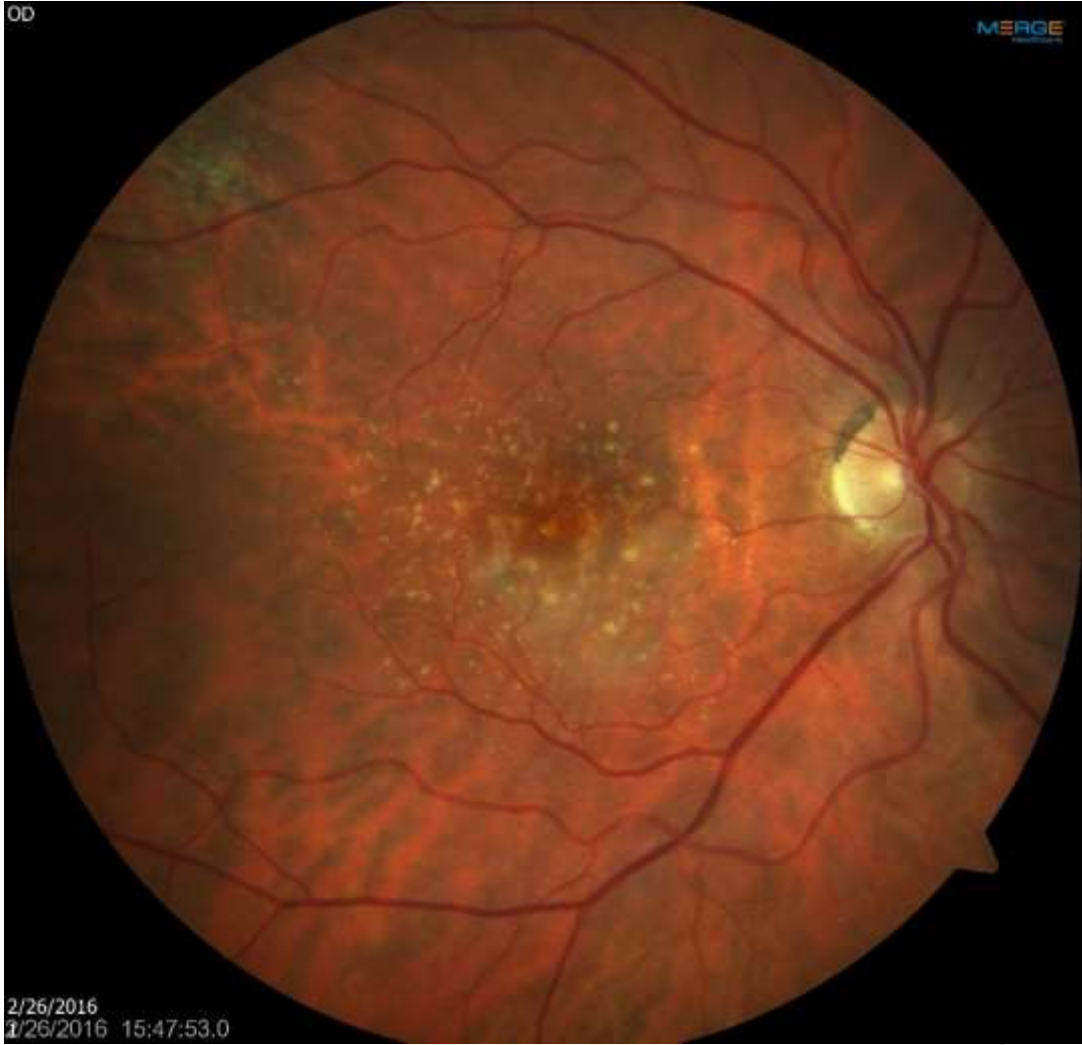- ▶ Very rare
- ▶ Bilateral
- ▶ Perifoveal capillary obliteration and telangiectasias
- ▶ Minimal exudation
- ▶ Associated with systemic or cerebral disease.
- ▶ Poorly understood



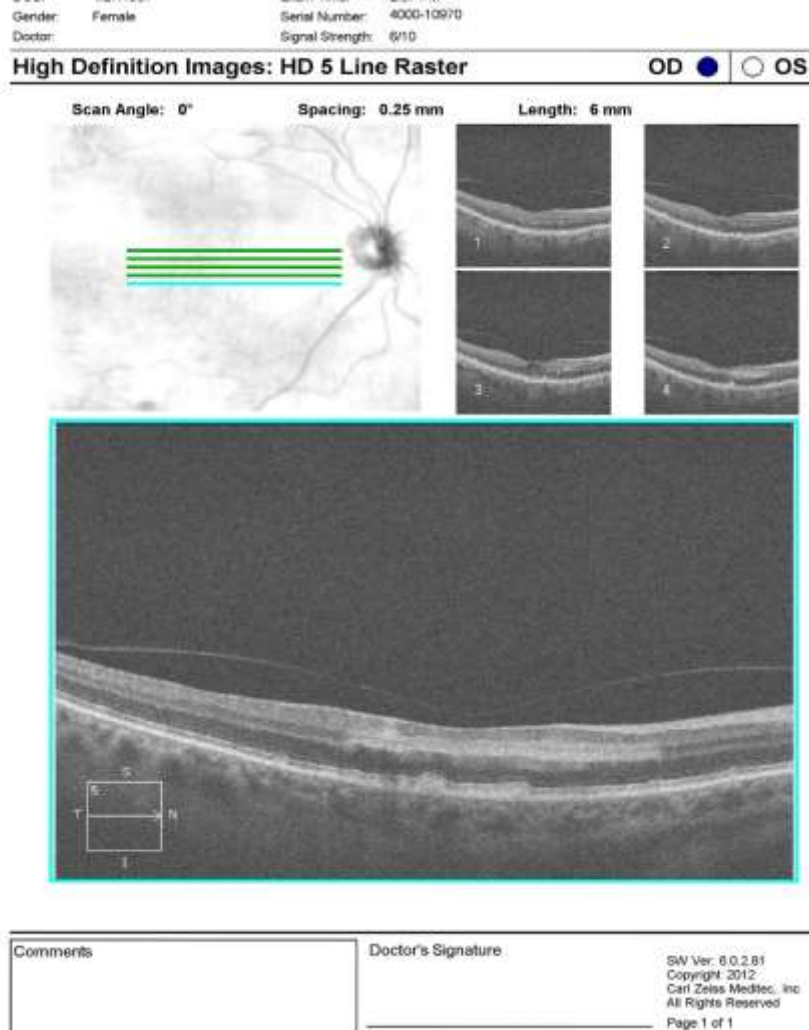
Middle maculopathy

- ▶ Paracentral acute middle maculopathy (PAMM)
- ▶ Older acute macular neuroretinopathy (AMN)
- ▶ PAMM affects middle retina (INL) and is an infarct of the intermediate capillary plexus
- ▶ AMN affects the outer retina (OPL/ONL/PIL line area) and is an infarct of the deep capillary plexus
- ▶ Can be younger supposedly healthy patients
- ▶ Can have a flu like prodrome
- ▶ Unilateral or bilateral
- ▶ Sudden onset of central or paracentral scotoma
- ▶ Slow resolution of defect, but may be permanent
- ▶ Can be seen with diabetes and other vascular or retinal vascular conditions / vasculitis
- ▶ No treatment other than underlying disease management

Middle Maculopathy (PAMM)



Middle Maculopathy (PAMM)

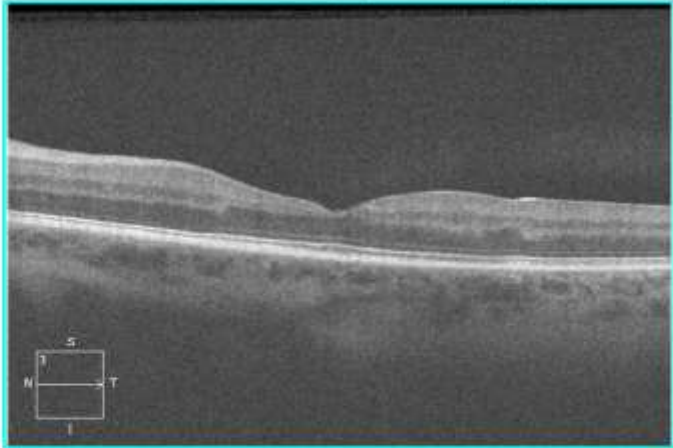
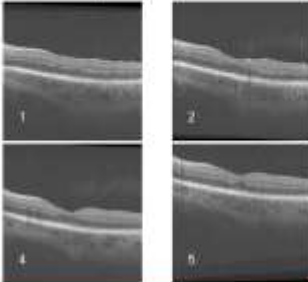
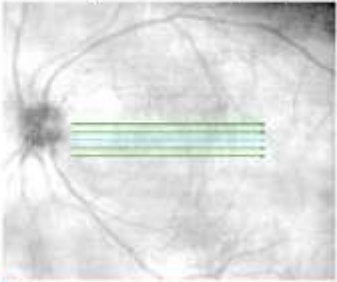


Old PAMM

Gender: Male Serial Number: 4000-10070
Technician: Operator, Cirrus Signal Strength: 8/10

High Definition Images: HD 5 Line Raster OD OS

Scan Angle: 0° Spacing: 0.25 mm Length: 6 mm



Comments _____ Doctor's Signature _____

SW Ver: 6.10.117
Copyright 2015
Carl Zeiss Medtec, Inc
All Rights Reserved
Page 1 of 1

12/5/2015
2

Artery Occlusions

- ▶ Embolus vs. local thrombosis
- ▶ Other factors include vasospasm, necrosis, GCA (10%), and hyperhomocystinemia
- ▶ Can affect the ophthalmic artery, cilioretinal arteries, and retinal arteries
- ▶ Hollenhorst plaque : 3X mortality
- ▶ Risk after facial filler injections
- ▶ 2.3 x risk of CRAO in patients with diabetes

Types of embolic plaques

- ▶ Hollenhorst (cholesterol) ; about 80% of retinal emboli
- ▶ Calcific; about 6 % of retinal emboli
- ▶ Fibrino-platelet; about 14% of retinal emboli

- ▶ H-H plaque mortality:
 - ▶ 15 % @ 1 year
 - ▶ 29 % @ 3 years
 - ▶ 54% @ 7 years

CRAO

- ▶ CRAO characterized by sudden, painless, profound loss of vision. VA count fingers or worse in 75-90%
- ▶ Possible amaurosis fugax
- ▶ Retina can appear normal for first hour or so

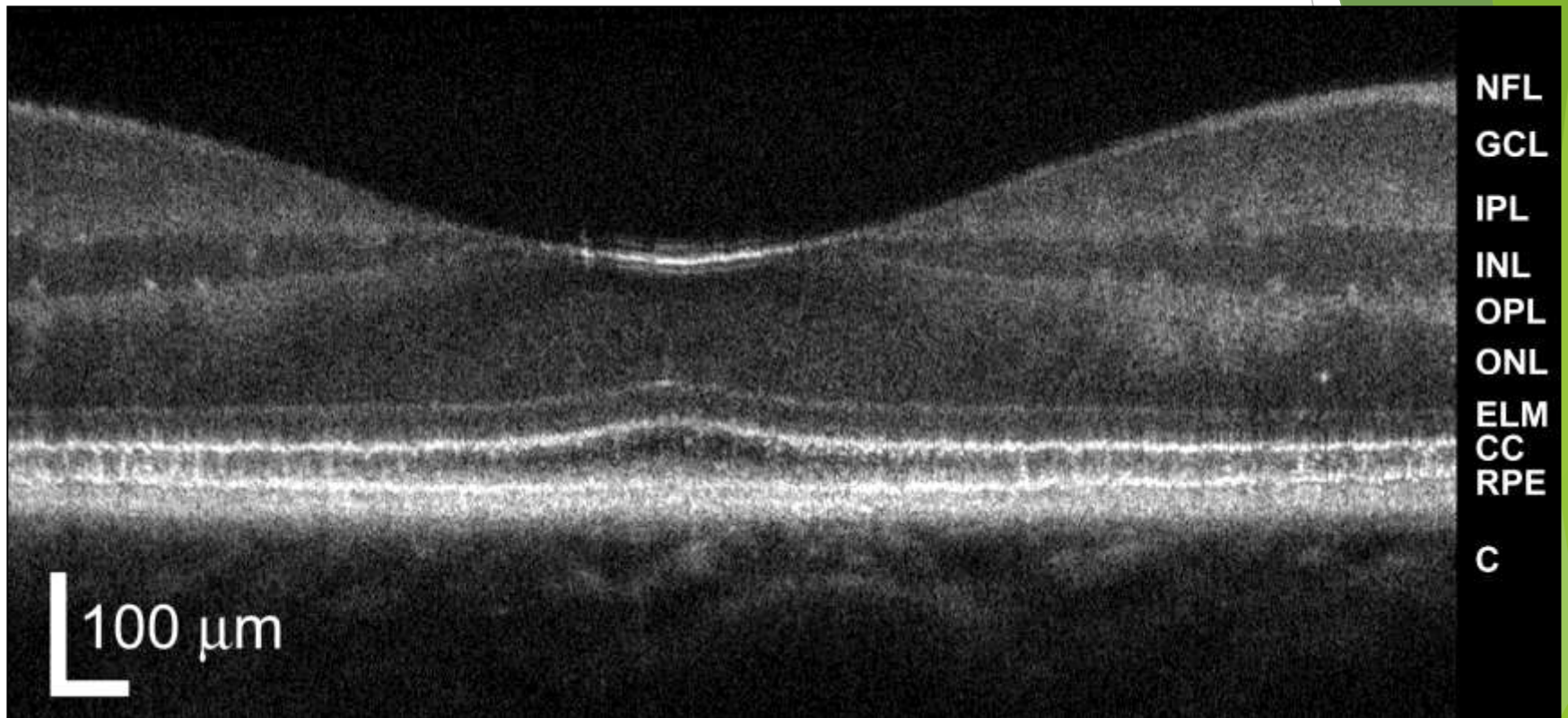
CRAO

- ▶ Emboli visible in only 20% of cases (carotid, heart valves)
- ▶ Within hours the retina (posterior pole) becomes white and opaque due to ischemic NFL edema.
- ▶ Cherry red spot due to lack of ganglion cells in the foveola

Cherry Red Spot



Spectral Domain OCT



Courtesy of Dan Hammer, PSI

CRAO

- ▶ Over the course of about one month, the retinal appearance returns to normal
- ▶ Residual optic atrophy / vessel attenuation long term
- ▶ 25-40% of cases have some sparing of the macular area due to cilioretinal artery perfusion

CRAO

- ▶ Sparing can result in reasonable visual recovery
- ▶ Without cilioretinal vessel perfusion, VA does not make a meaningful recovery in most cases
- ▶ NVI,NVD,NVE are very rare complications
- ▶ Why is that?

CRAO


- ▶ Giant cell arteritis, drops in perfusion pressure, ONH drusen, sickle cell are non-embolic causes
- ▶ Life expectancy of 5.5 years compared to 15.4 years for age matched
- ▶ Treatment is notoriously ineffective
- ▶ Digital massage, IOP lowering (paracentesis), rebreathing in paper bag
- ▶ What are we really doing?
- ▶ Possibly TPA?
- ▶ ? ND-YAG lysis of emboli
- ▶ ? Hyperbaric Oxygen

Intravenous TPA

- ▶ Very controversial
- ▶ Some deaths from cerebral and hepatic hemorrhaging with Streptokinase in various trials
- ▶ Short window to be effective: likely must be within 4.5 hours of symptom onset. Practically, this is very unlikely to occur
- ▶ One meta-analysis of available trials and studies showed that patients starting with VA of 20/200 or worse, the chance of improving to 20 / 100 or better was.....
- ▶ 17.7% without intervention
- ▶ 7.4% with traditional massage / paracentesis, etc.
- ▶ 50% with IV TPA within the first 4.5 hours
- ▶ Many questions remain, however

CRAO: Hyperbaric Oxygen therapy

- ▶ 2018 Meta Analysis of 7 RCT's, 251 patients
- ▶ Oxygen therapy delivered early = 5.61 X chance of improved vision
- ▶ 100% hyperbaric O₂ delivered soon after event for 9 or more total hours best



Types

- ▶ Believed to be four sub types of CRAO.....each with a unique natural history (SS Hayreh)
 - ▶ I) NA-CRAO
 - ▶ II) NA-CRAO with C-R artery sparing
 - ▶ III) Transient NA-CRAO
 - ▶ IV) Arteritic CRAO

CRAO

- ▶ Chance of any degree of visual recovery depends entirely upon sub-type
- ▶ Transient NA-CRAO and NA-CRAO with CR artery sparing may improve
- ▶ Improvement possible over first seven days or so

BRAO

- ▶ BRAO's occur less frequently than do CRAO's (?) 68% have visible embolus
- ▶ A smaller embolus , usually temporal to the macula (80%)
- ▶ Appearance is similar but in a localized area
- ▶ Susac syndrome (triad of encephalopathy, BRAO's, and hearing loss) most common in young women.

BRAO

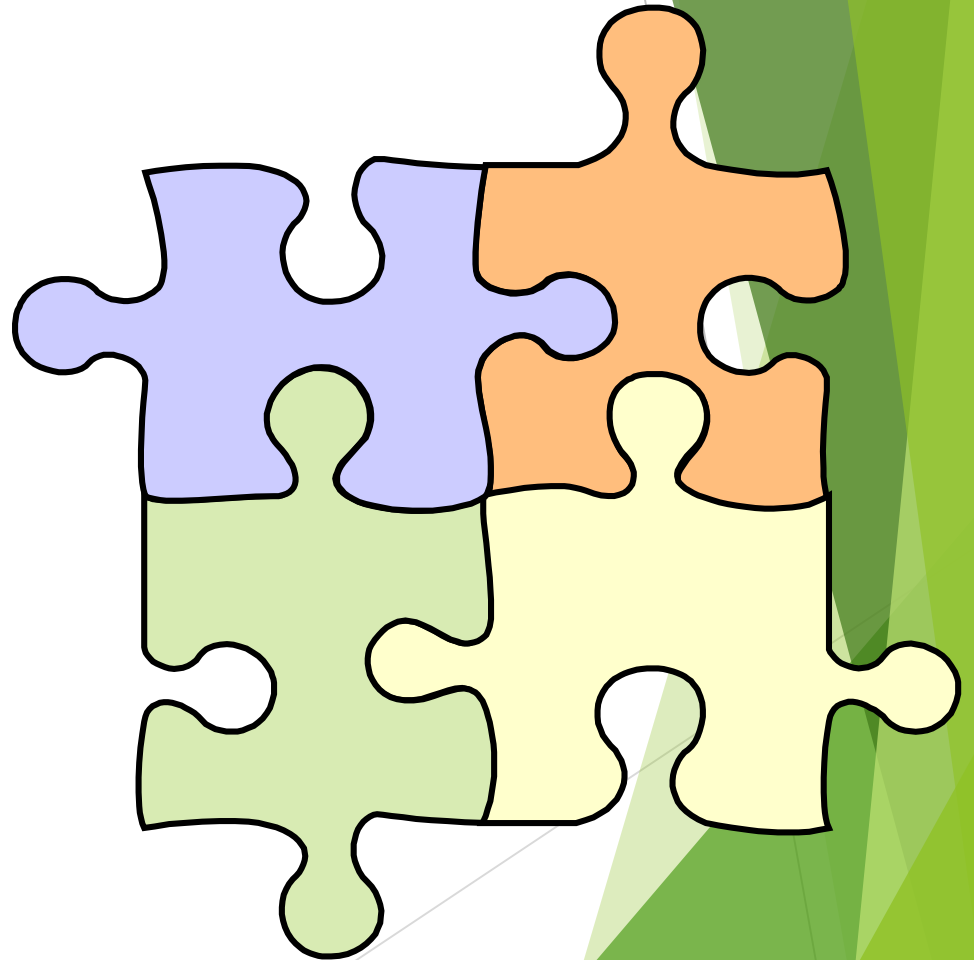
- ▶ VA usually good: scotoma!
- ▶ Survival rates are actually lower than for CRAO
- ▶ Cilioretinal and ophthalmic artery obstructions are also possible: think GCA!

BRAO / CRAO

- ▶ Ophthalmic artery obstruction mimics CRAO but vision is usually NLP, there is no cherry red spot, and the findings are more pronounced
- ▶ Get carotids (cholesterol) and heart valves (calcium) checked as indicated.....? Yield. GCA
- ▶ Doppler of carotid checks neck only.....not sections in thorax and skull
- ▶ Presence of plaques may be more important than level of stenosis (microemboli)
- ▶ Why would that be?

Hollenhorst plaques

- ▶ What testing is indicated?
- ▶ Article by Varner with literature review yielded some surprises (Clinical Optometry 2013:5, 13-17)



Hollenhorst plaque

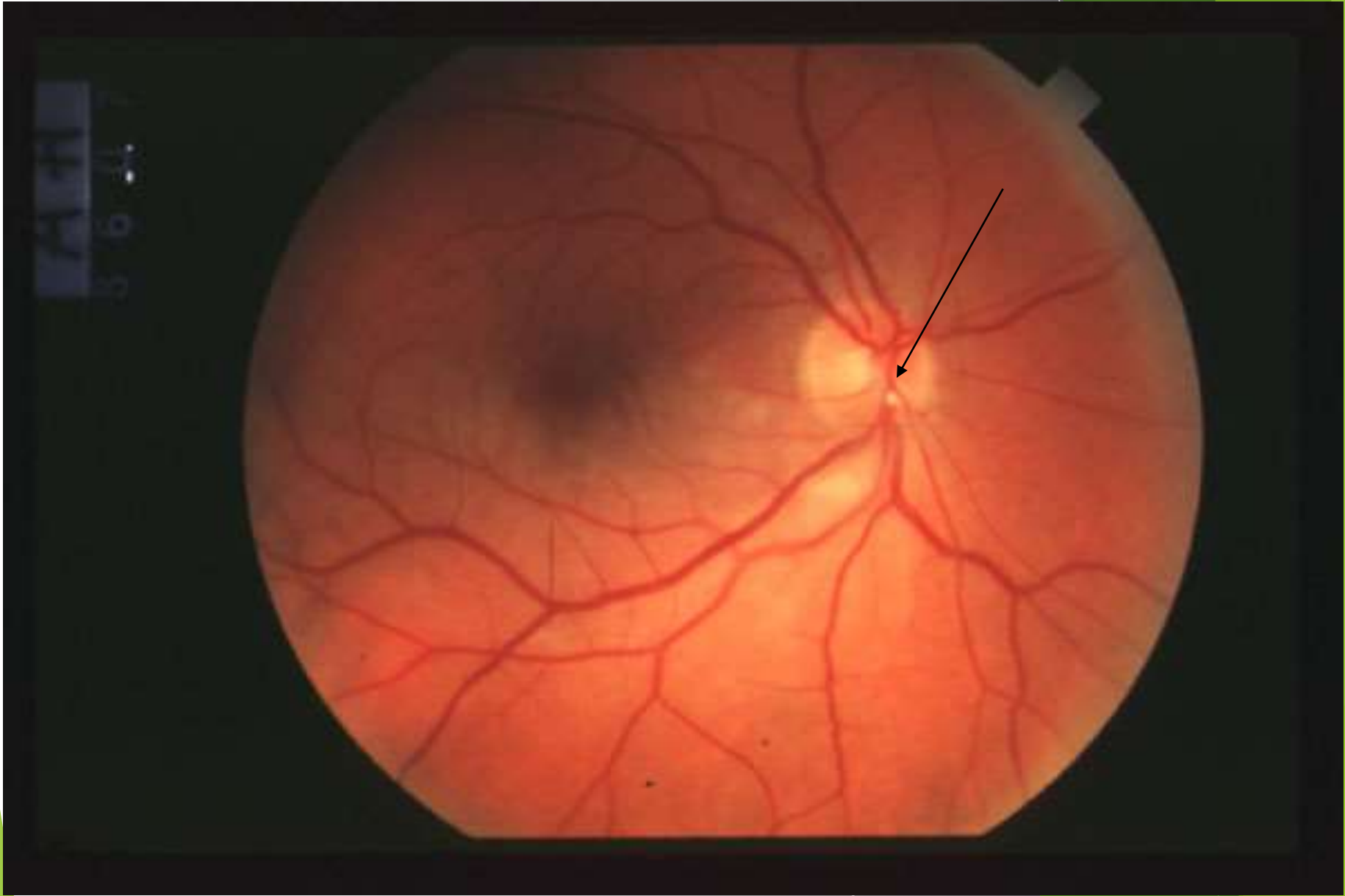
- ▶ HHP with No visual symptoms and known cardiovascular disease > No Doppler. Consider 81mg Aspirin
- ▶ HHP with visual symptoms > Doppler indicated
- ▶ HHP with no known cardiovascular disease > full cardiovascular work-up
- ▶ Carotid Auscultation for bruits not useful in patients with HHP but no visual symptoms

What about acute (often “silent”) strokes with CRAO / BRAO

- ▶ One study found that 24% of patients with ocular TIA’s suffered an acute cerebral stroke at the same time. Often symptom free (“silent”)
- ▶ A second study looked at 33 patients with new onset CRAO or BRAO. 24% of them had concurrent acute (<14 days) cerebral strokes. Again, often “silent”
- ▶ Even more, newer reports as well finding the same thing

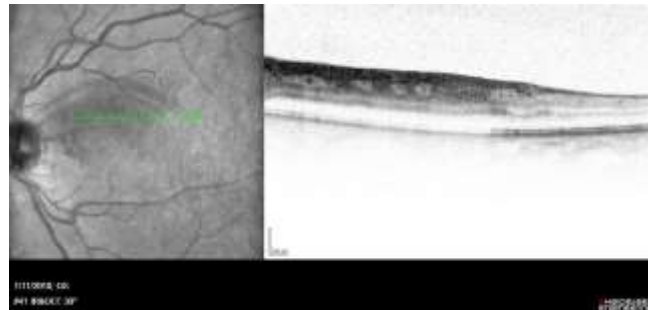
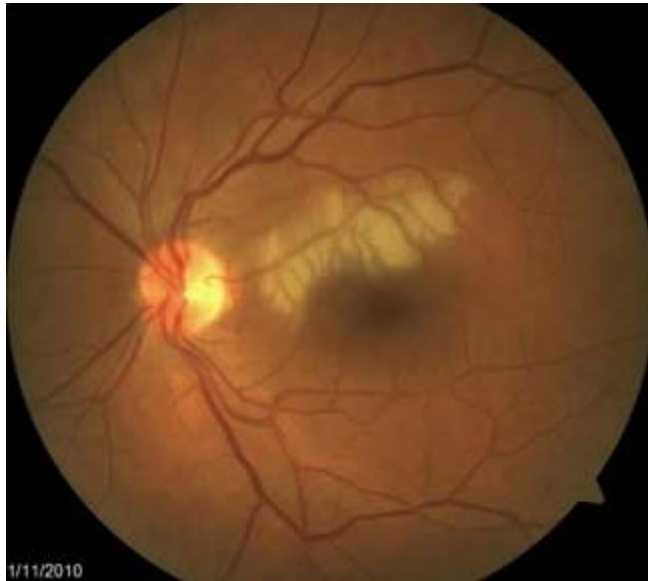Acute strokes with CRAO / BRAO

- ▶ Must run diffusion-weighted MRI, not standard T2-weighted MRI
- ▶ It better distinguishes acute infarcts from old lesions
- ▶ Recommendation from these studies, editorials, the American Heart Association and the National Stroke Association: Obtain emergent diffusion weighted brain MRI, preferably in a stroke center, on ALL patients with ocular TIA, BRAO, or CRAO
- ▶ Some controversy still, for several reasons (cost, what is then done, etc.)

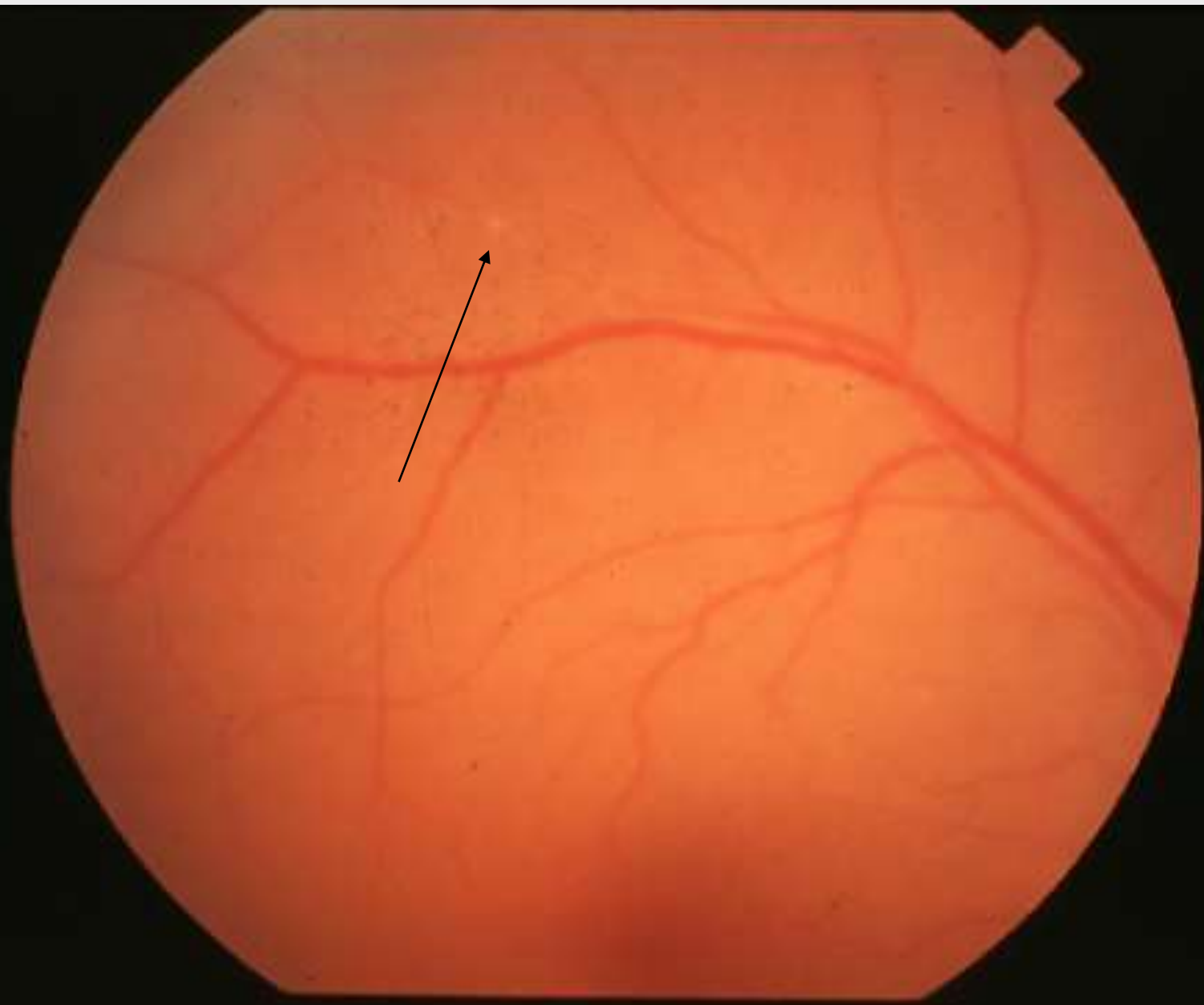


Cilioretinal Artery Occlusion

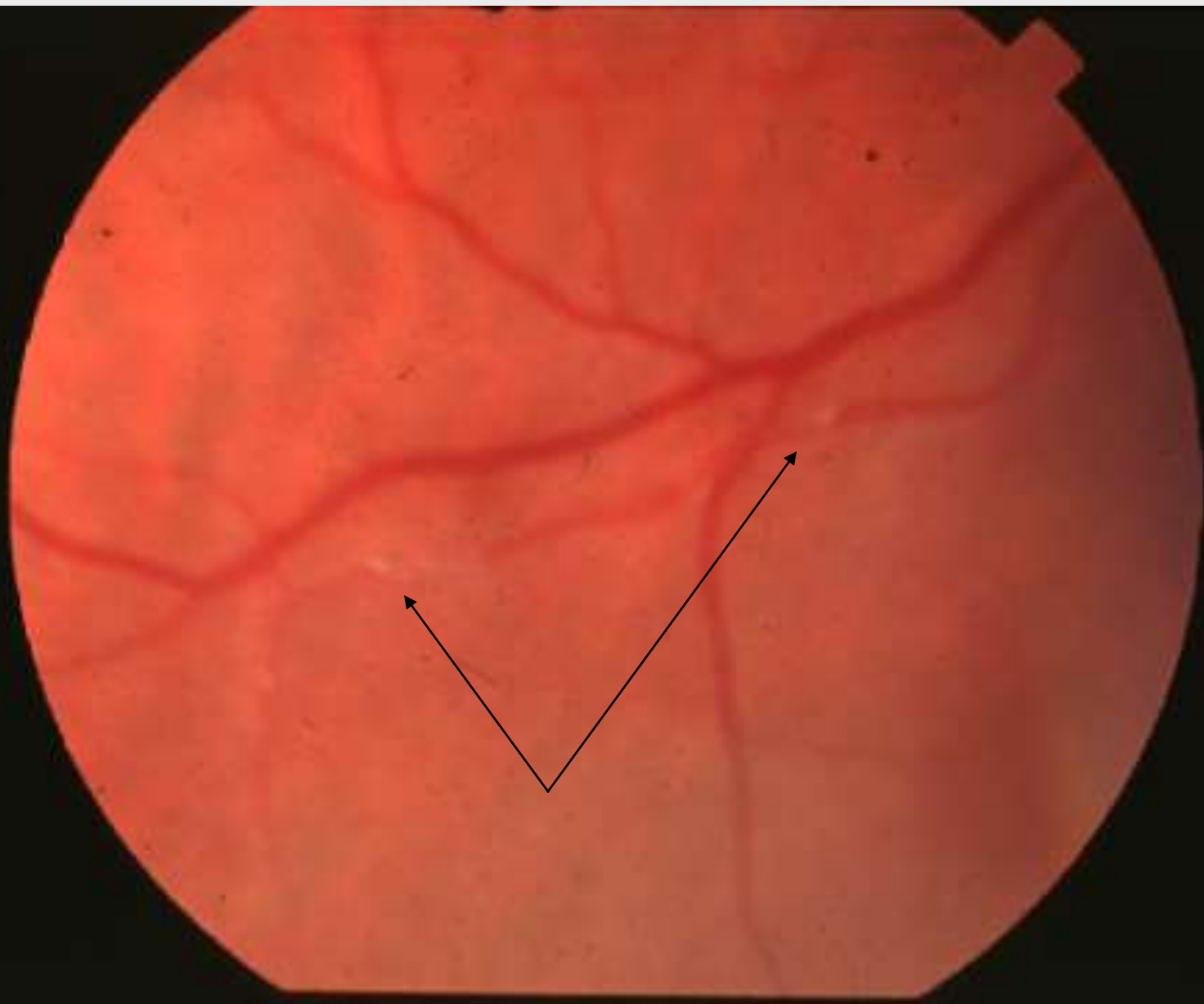
Courtesy Dr.
Mohammad
Rafieetary



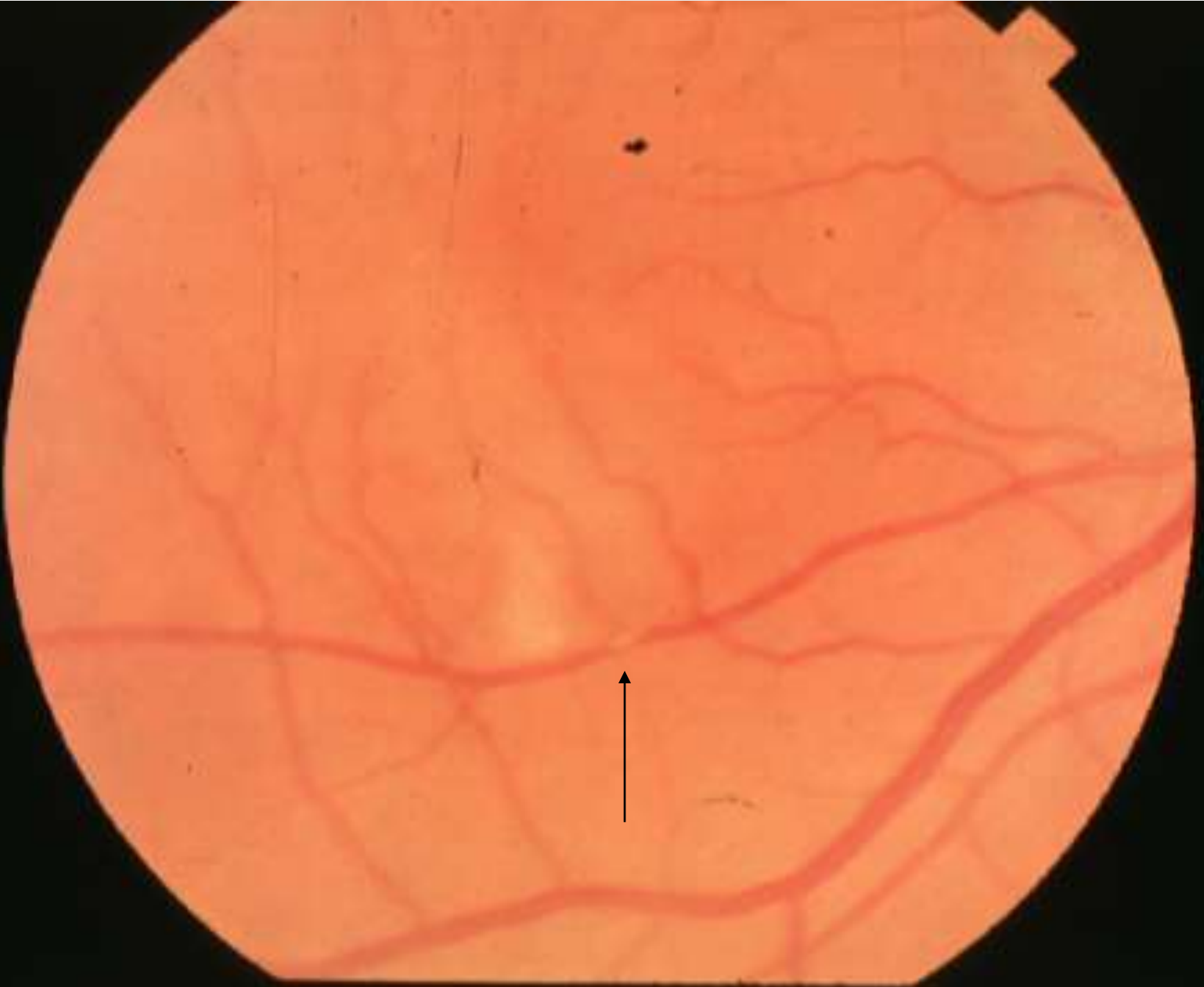
3.9.5.0



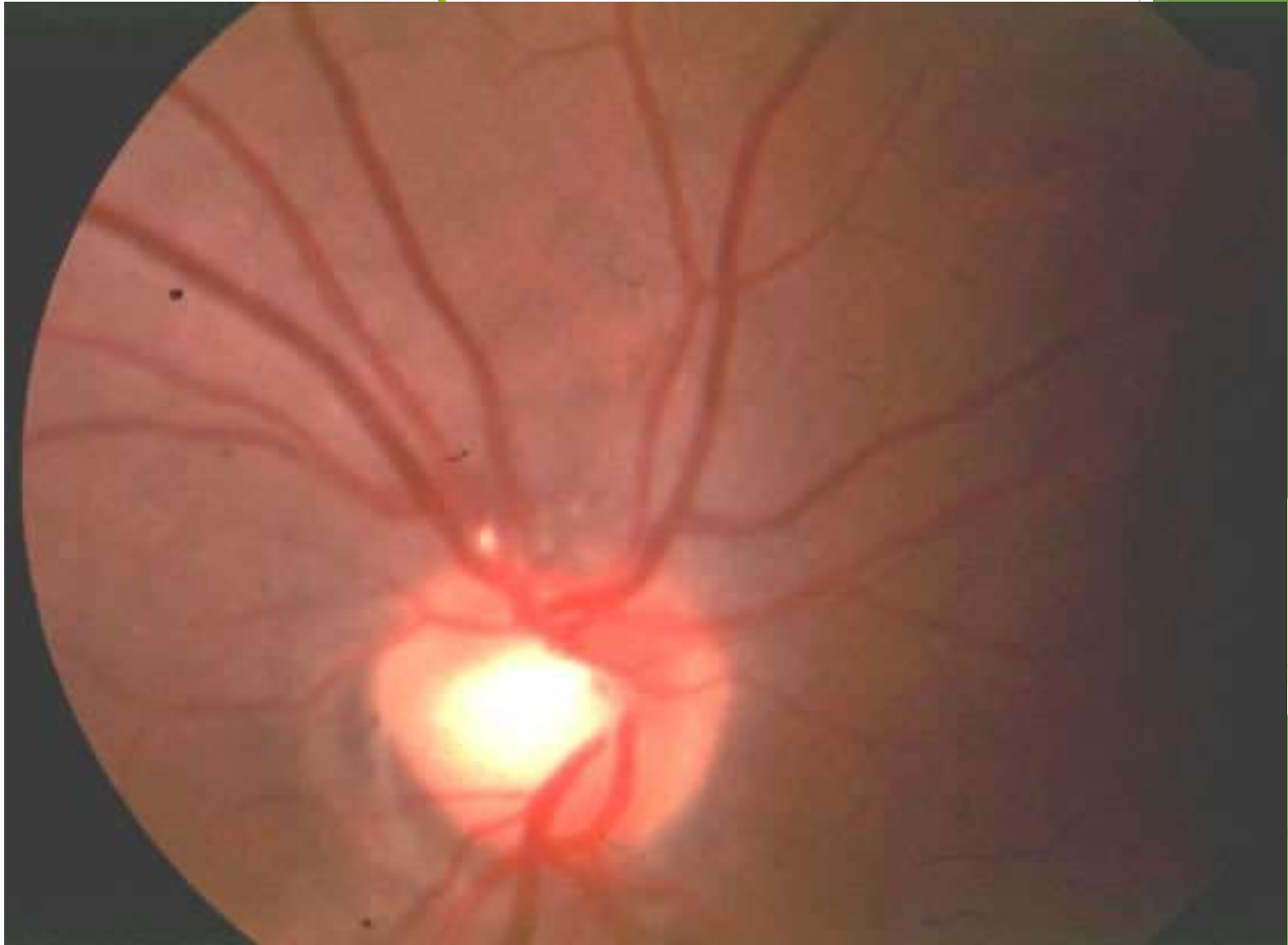0.0.2.1



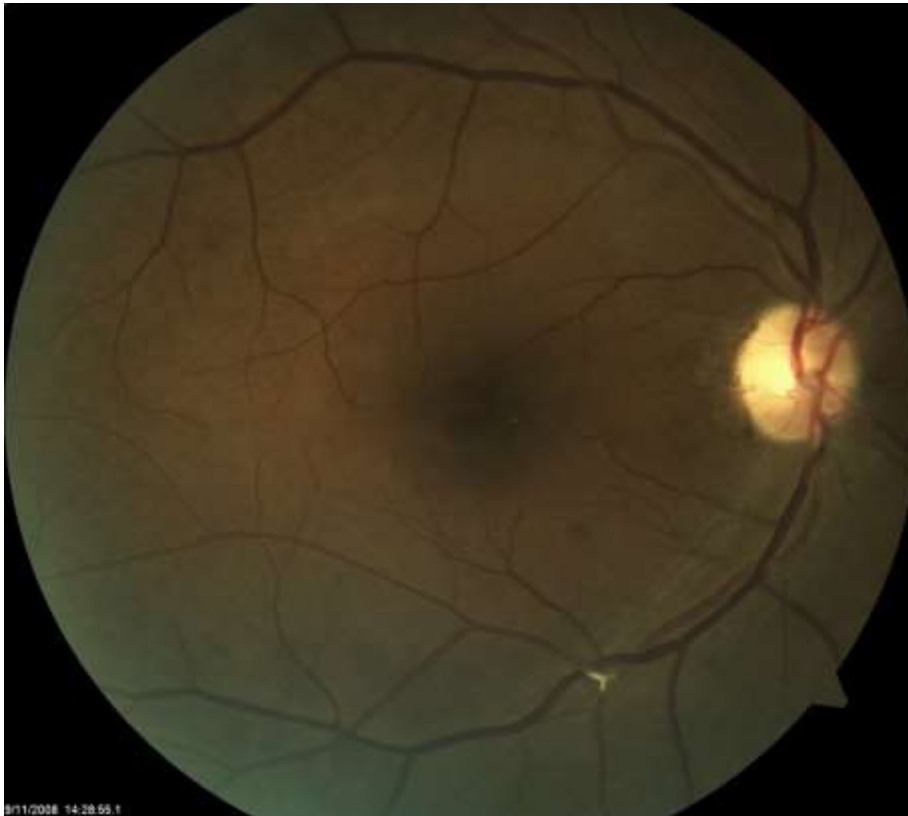4988



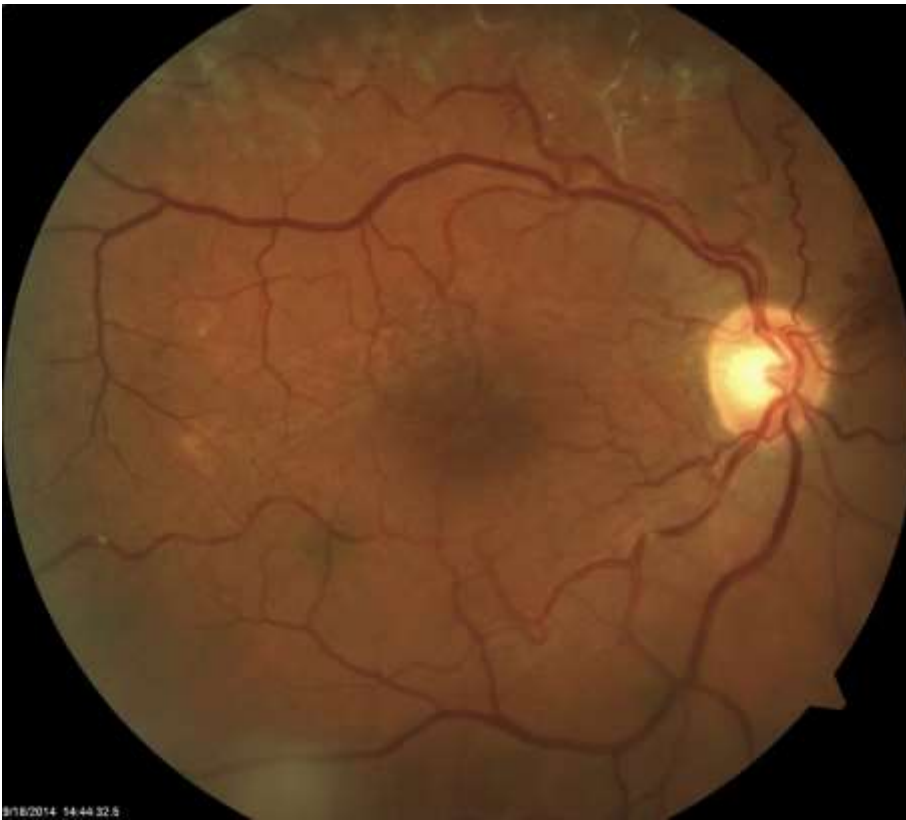Calcium Plaque



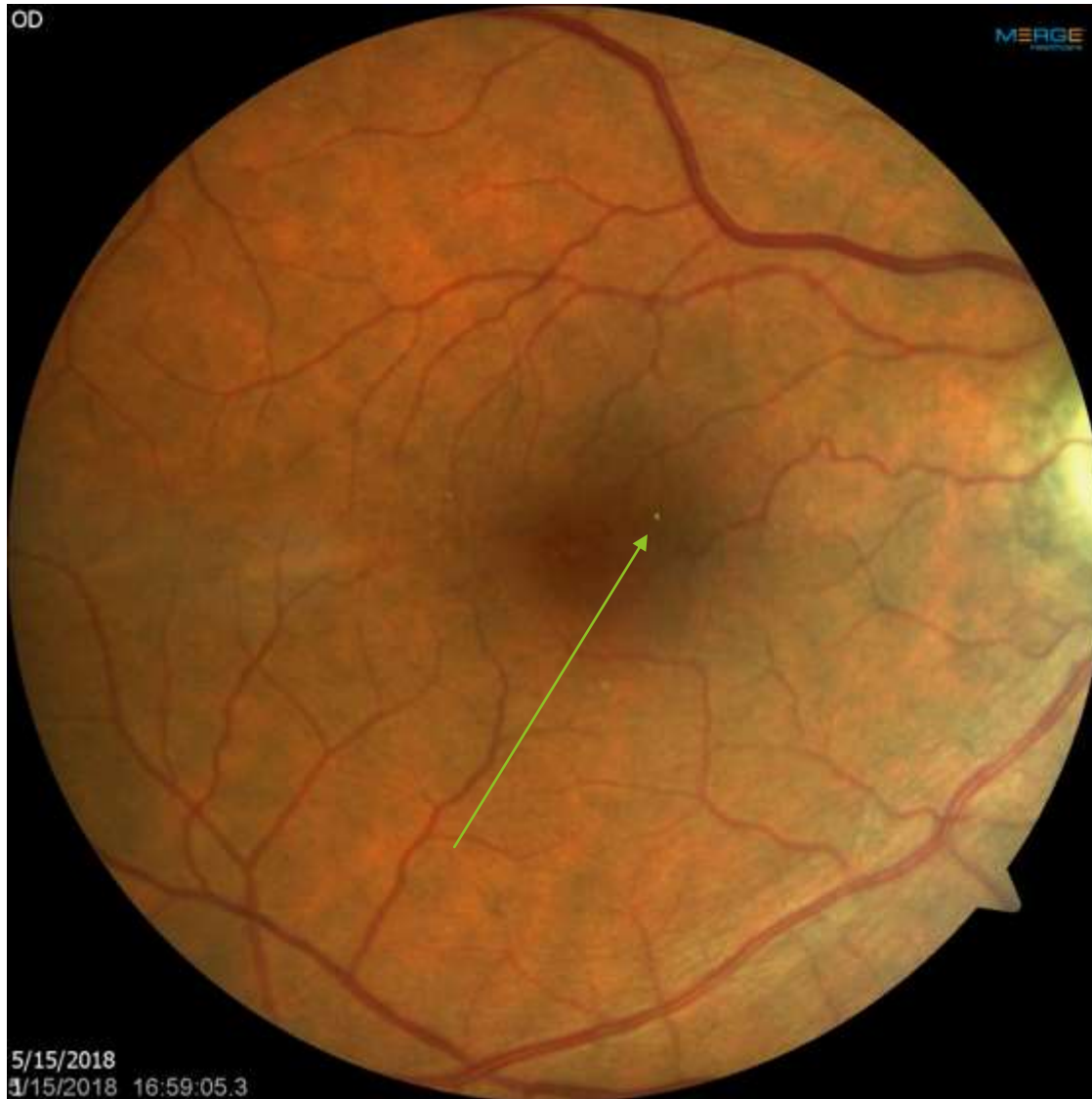Bifurcation fibrinoplatelet plaque



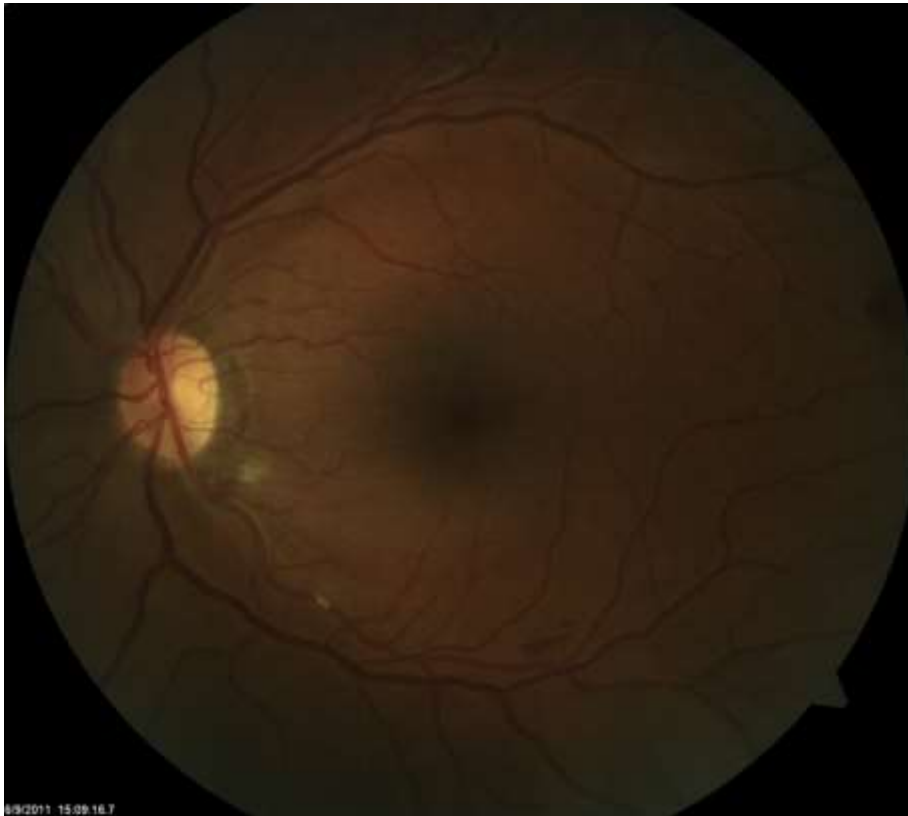HH Plaque



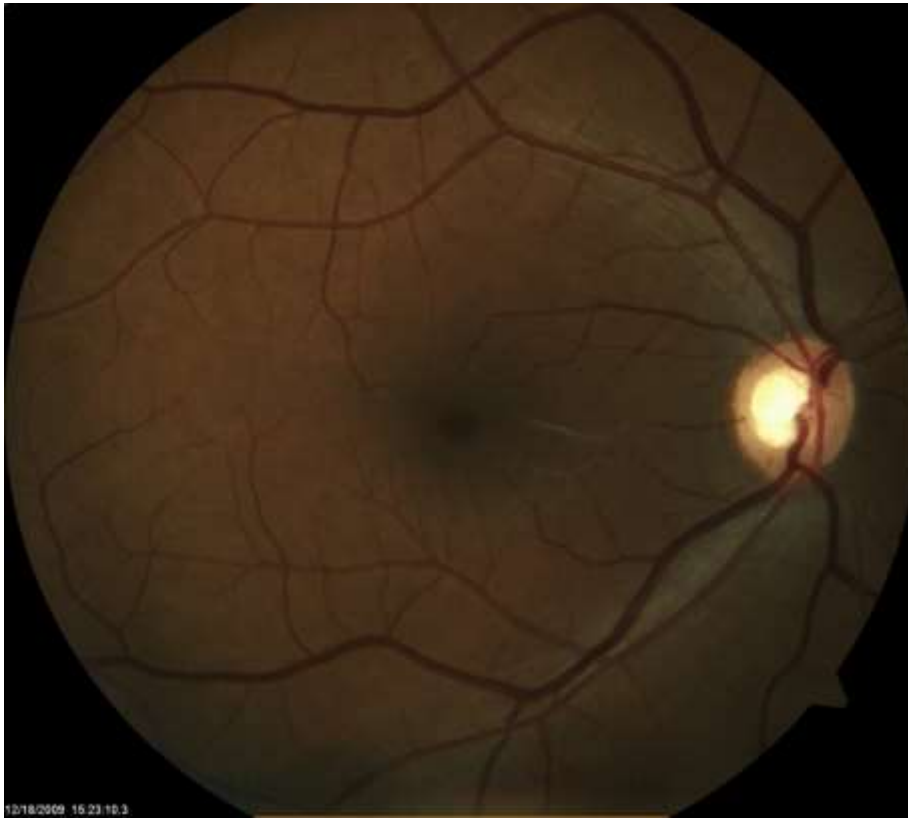HH Plaque



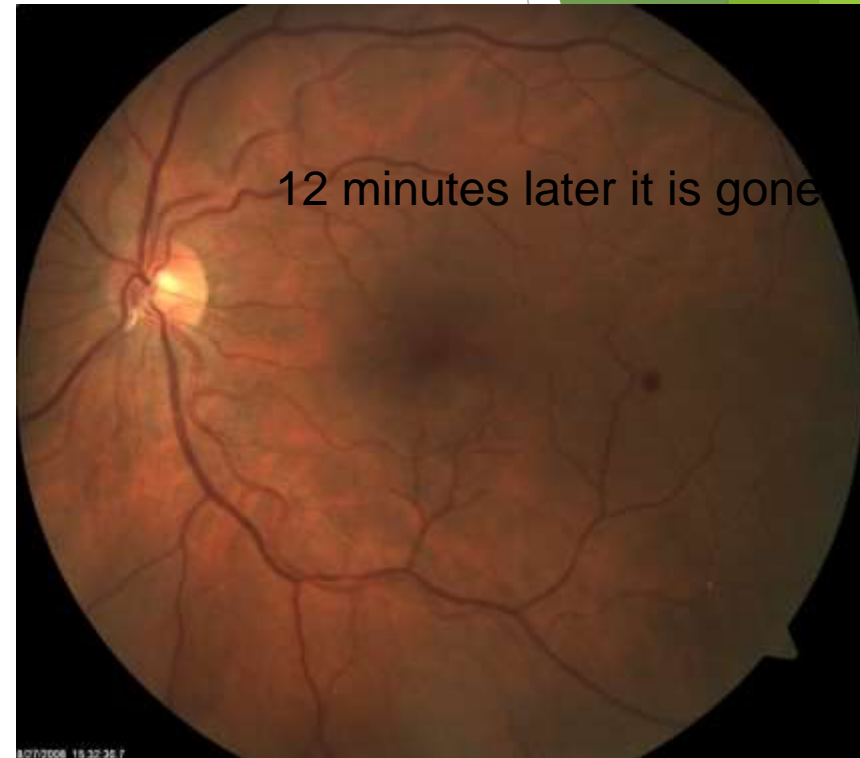
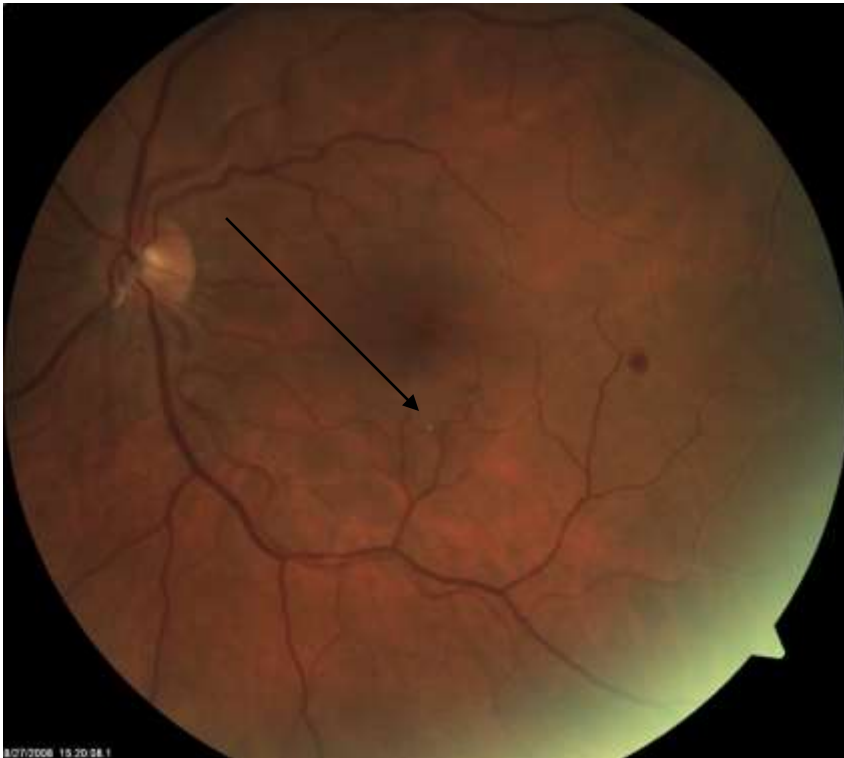fibrinoplatelet plaque



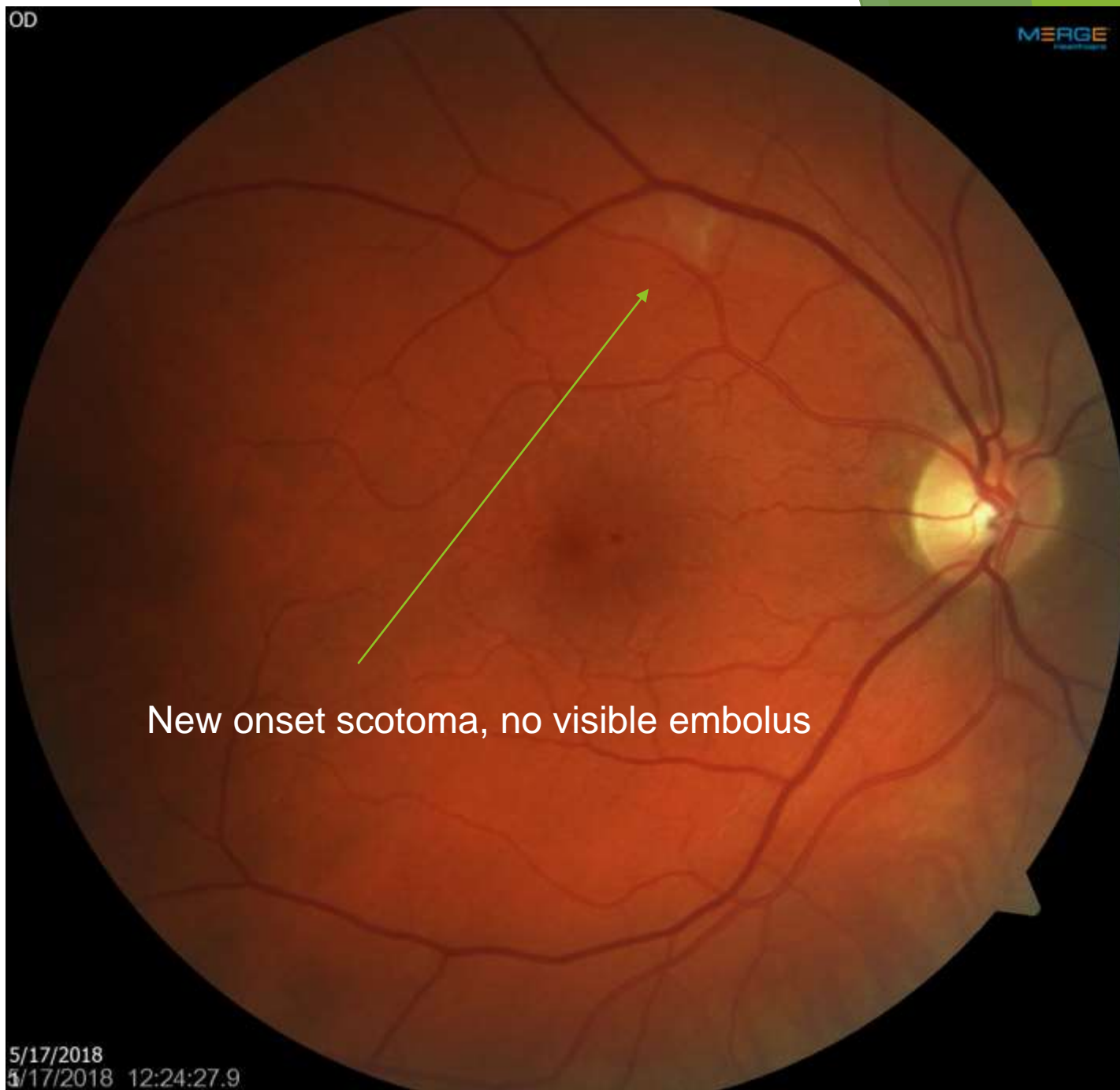Cilioretinal artery sclerosis



Now you see it.....



BRAO



Retinal Vein Occlusions

- ▶ CRVO or BRVO
- ▶ Leading cause is hypertension (branch>central) but others include hypercoaguable states, thrombi, and atherosclerotic events. 20% associated with POAG. Link with OSA
- ▶ Second only to DBR in frequency
- ▶ Occlusion of vein leads to dilated and ruptured capillaries, often with edema

CRVO


- ▶ Most patients 50+
- ▶ 50+% have systemic association: linked to IOP
- ▶ Often increased Homocysteine levels, APA
- ▶ Presenting symptom is a sudden, painless loss of vision
- ▶ Two types: ischemic and non-ischemic.

Non-Ischemic CRVO

- ▶ Non-ischemic CRVO (up to 80% of cases) has a less severe presentation and better prognosis
- ▶ VA moderately reduced; often 20/60 to 20/100
- ▶ No APD typically
- ▶ 2/3 have 20 / 40 + final VA
- ▶ Less capillary non-perfusion on IVFA
- ▶ No neovascular complications

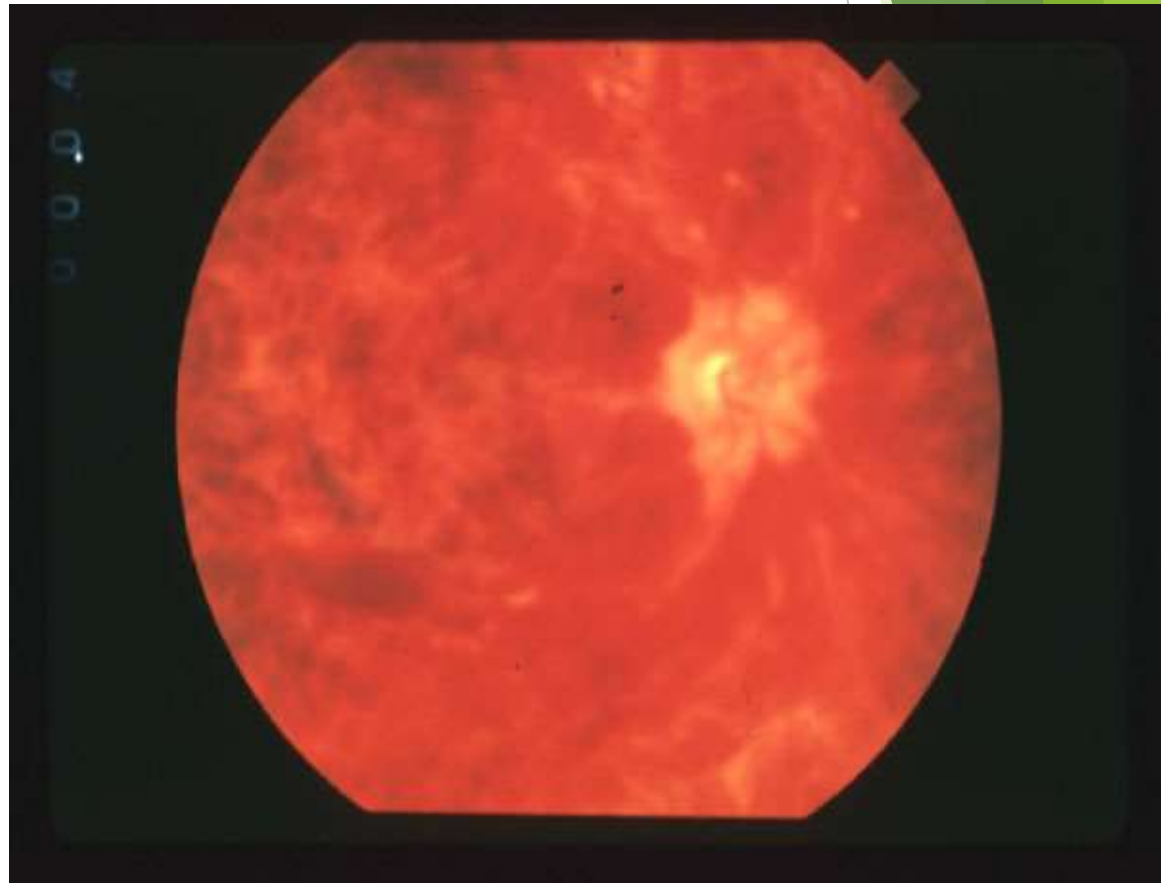
Ischemic CRVO

- ▶ Ischemic CRVO much more severe
- ▶ VA markedly reduced, usually 20/200 or worse



Ischemic CRVO

- ▶ + APD
- ▶ Massive hemes in all four quadrants



Ischemic CRVO

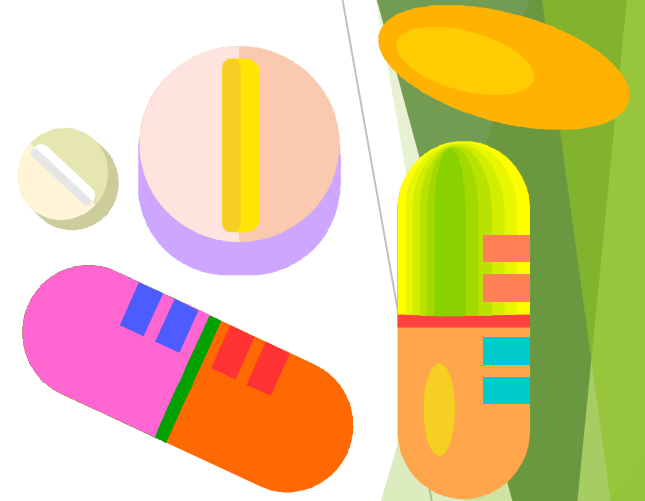- ▶ Severe macular edema, may get disc edema
- ▶ More CWS than non-ischemic
- ▶ IVFA / OCTA shows significant capillary dropout and non-perfusion
- ▶ Prominent middle limiting membrane (MLM) on SD-OCT at outer plexiform layer
- ▶ NVI very common, NVD and NVE less so???
- ▶ Only 40-45% NVI get NVG
- ▶ *How could NVD and NVE be less common than NVI?

CRVO

- ▶ What do we do for the eye?
- ▶ Many more options than we used to have

Treatment

- ▶ ? Doppler of carotids in all cases: Carotid occlusion highly associated with CRVO (especially ischemic), but not causative



Surgical interventions

- ▶ Radial optic neurotomy
- ▶ Chorioretinal venous anastamoses
- ▶ Vitrectomy / ILM peel
- ▶ Cannulation of the vein with t-PA injection
- ▶ All historically tried and mostly abandoned

Intravitreal kenalog

- ▶ SCORE study
- ▶ Observation vs. 1mg/ml kenalog vs. 4mg / ml kenalog
- ▶ After six months:
 - ▶ Steroid injection 5 times more likely to get substantial VA improvement compared to observation
 - ▶ Watch for steroid side effects
 - ▶ Now also have steroid implants

Intravitreal Avastin / Lucentis

▶ CRUISE study
(Lucentis)

▶ .3mg/ml injection
vs. .5mg/ml
injection vs. sham
injection

At six months, gain
of.....

13 letters on EDRS
chart

15 letters

1 letter !

Laser therapy

- ▶ PRP still has a role if neovascularization develops
- ▶ Grid-focal laser really has no role typically in CRVO management
- ▶ Anti-VEGF injections have become the standard therapy, typically on a treat and extend basis: Avastin / Lucentis / Eylea (which of these is by far the most cost effective?)
- ▶ Several studies comparing the various agents to each other: basically they all work

RETAIN Study

- ▶ 34 BRVO and 32 CRVO patients receiving Lucentis shots followed over four years.
- ▶ At the four year mark.....
- ▶ Average vision gain achieved at six months was still present at four years
- ▶ But 50% of BRVO and 56% of CRVO patients were still getting shots four years out

SCORE II study

- ▶ CRVO and HRVO
- ▶ Injection at enrollment and every month thereafter
- ▶ Either 1.25 mg of Avastin or 2.0 mg of Eylea
- ▶ At 6 months.....
- ▶ Avastin and Eylea showed equal improvement in VA
- ▶ Eylea showed a greater reduction in central macular edema on OCT (but no better VA)
- ▶ Younger age, worse initial vision were correlated with more improvement in VA

In general.....

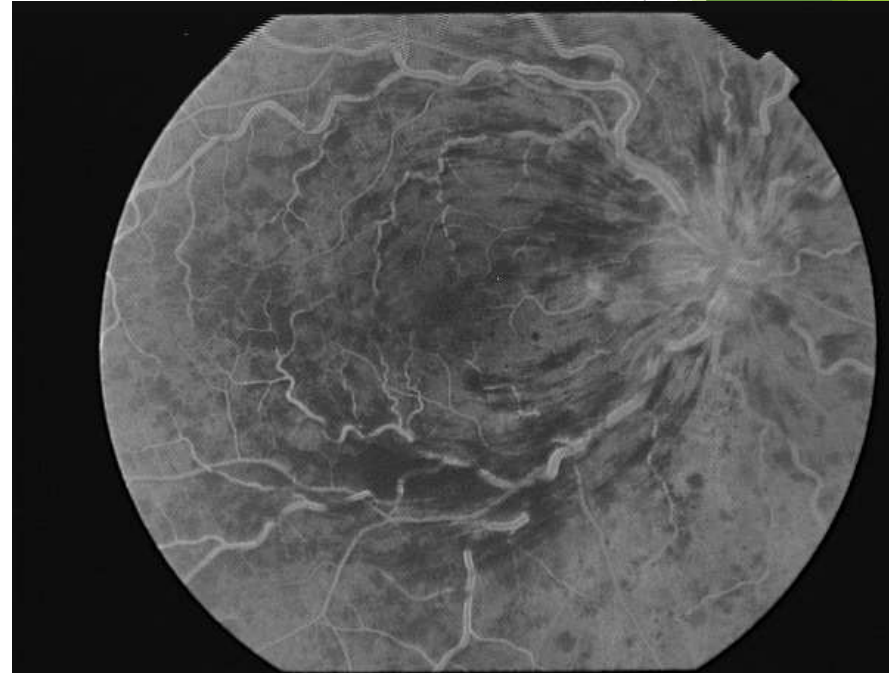
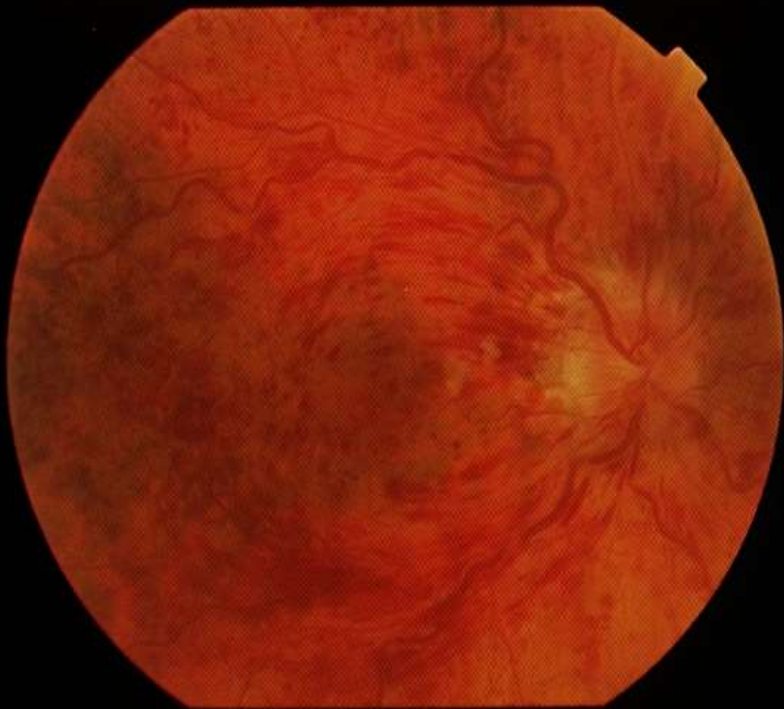- ▶ PRP advantage with neo.....
- ▶ Can permanently “fix” the problem by decreasing oxygen demand below the needed threshold
- ▶ PRP disadvantage....
- ▶ ERM formation
- ▶ Night vision loss
- ▶ Peripheral vision loss
- ▶ Longer treatment session

In general.....

- ▶ Anti-VEGF injection advantages.....
- ▶ Very low rate of side effects (endophthalmitis, elevated IOP with repeat injections)
- ▶ Work well, often very well
- ▶ Anti-VEGF injection disadvantages....
- ▶ Repeated injection after injection so issues with cost, transportation, “visit fatigue”, etc. Can need dozens of shots, less permanent

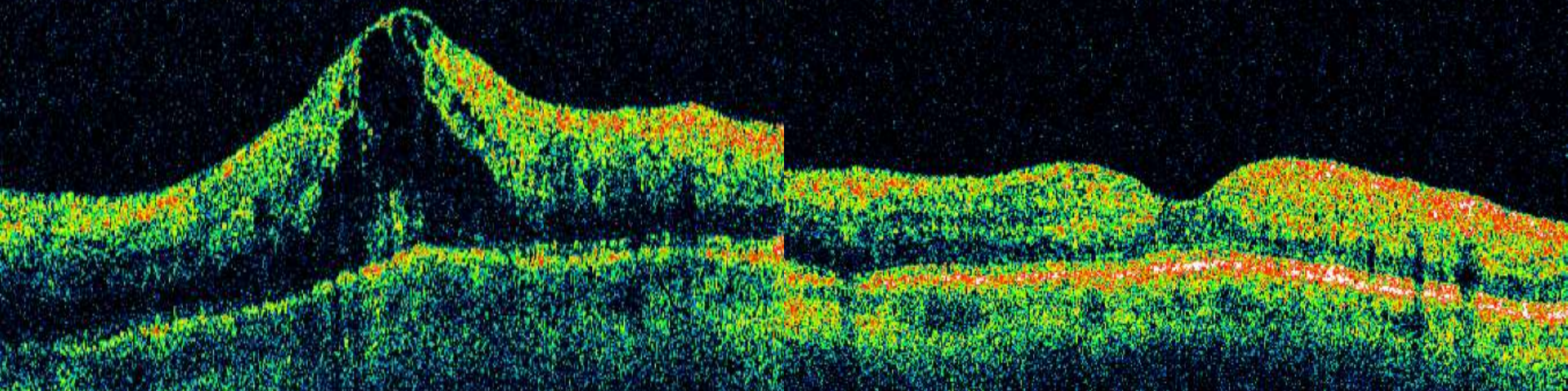
CRVO

- ▶ Non-ischemic



20/70

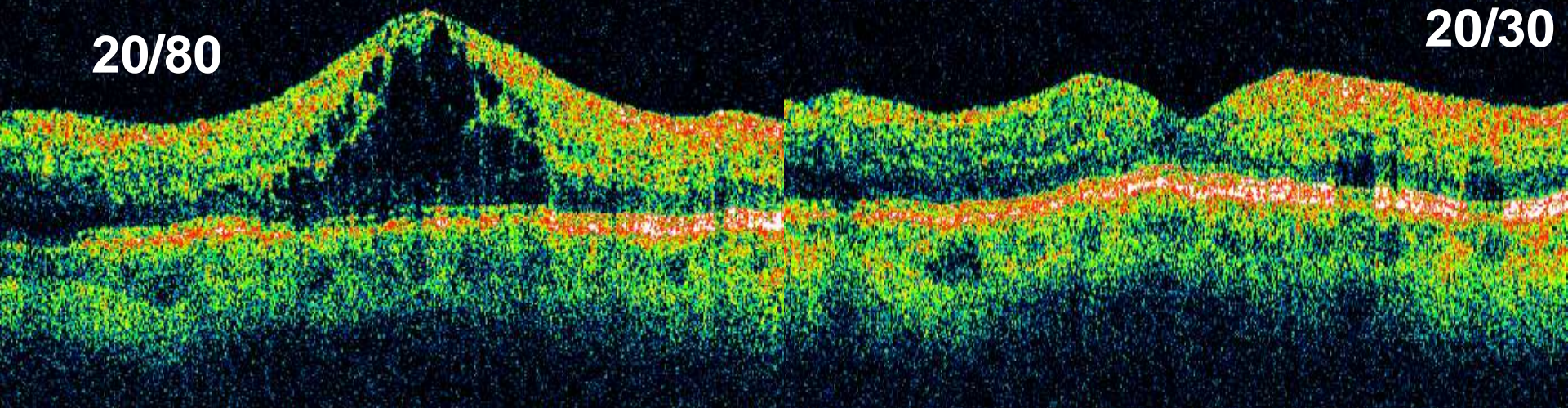
20/25



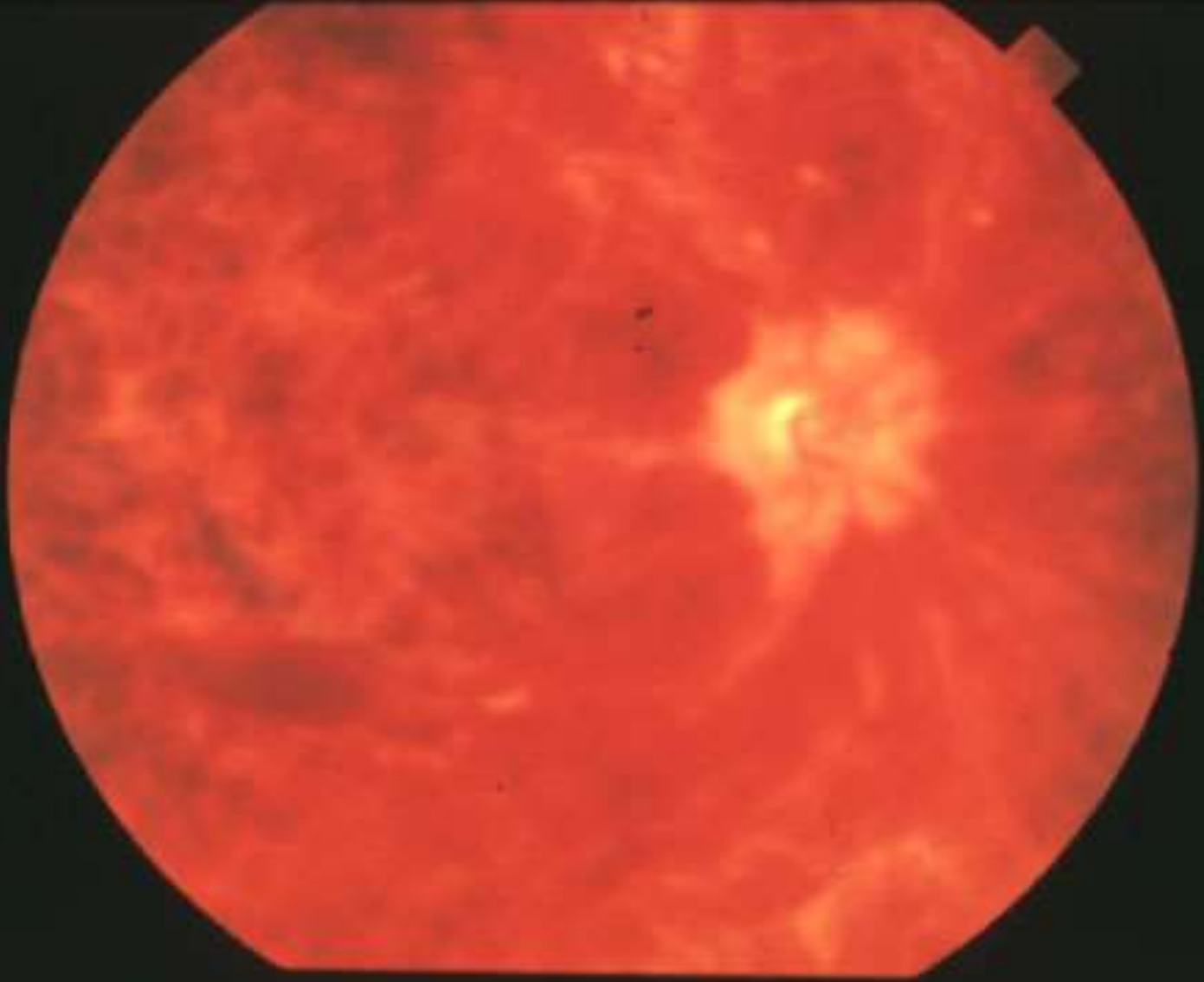
S/P 2 Intravitreal Steroid Injections

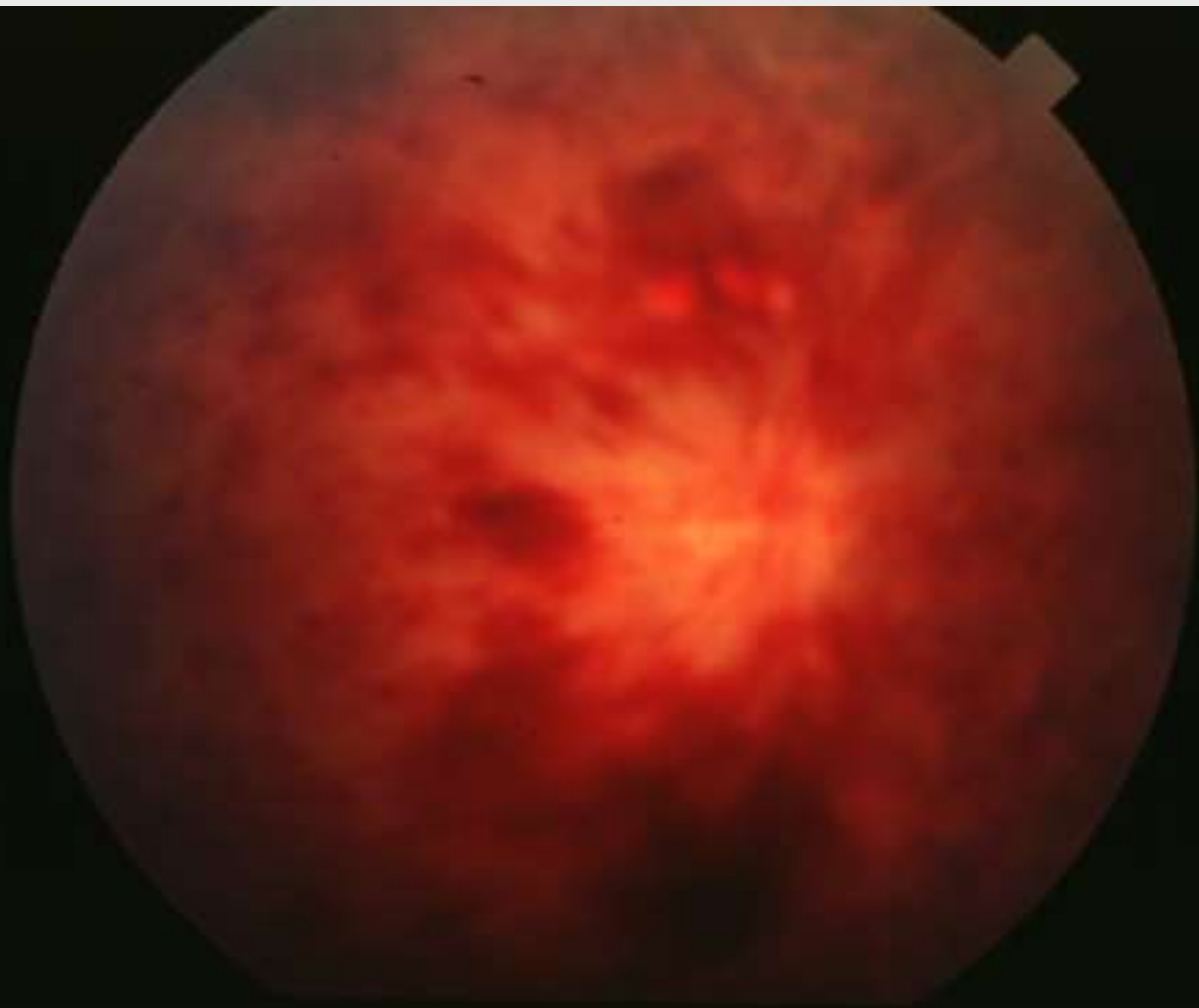
20/80

20/30

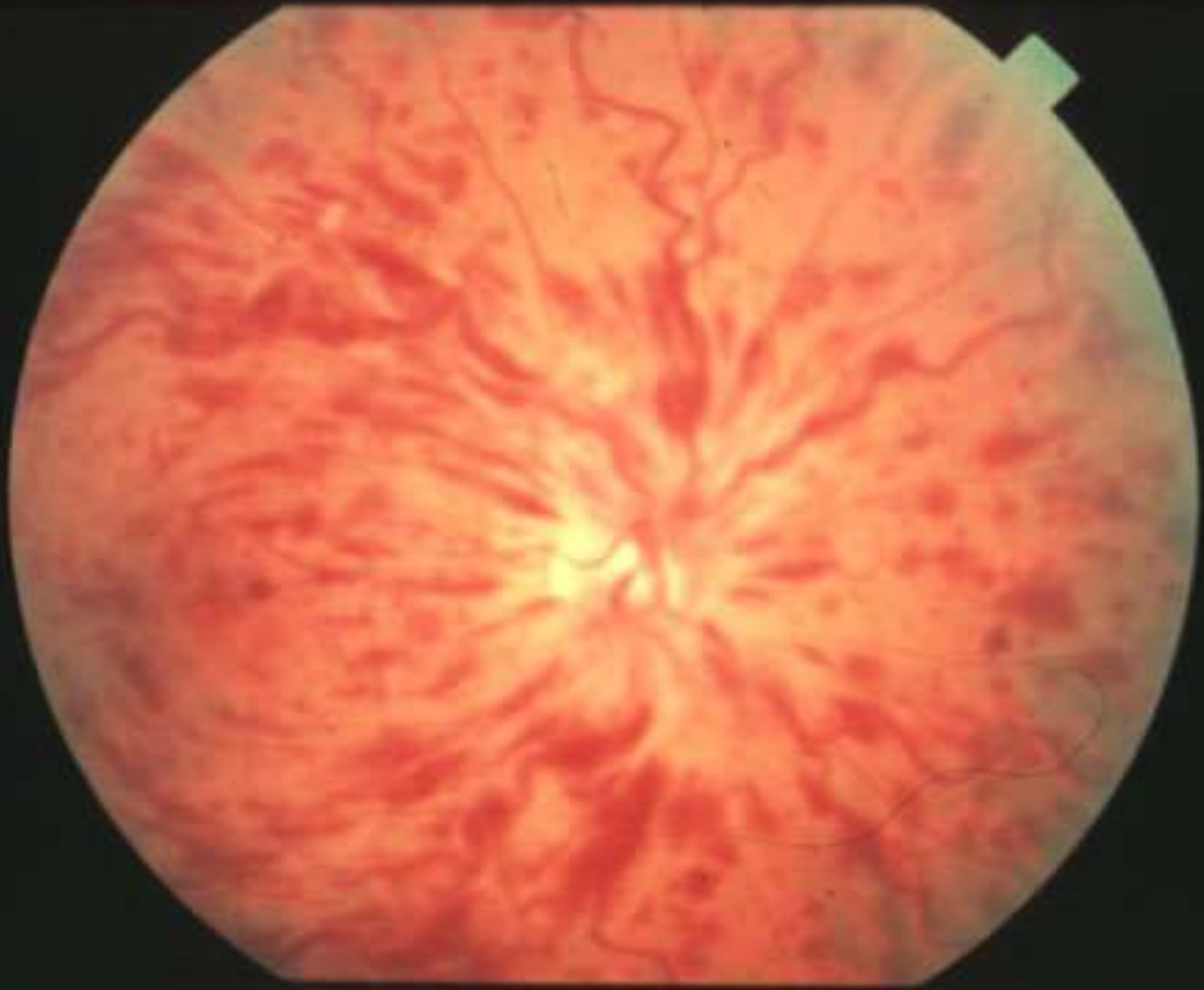

0004

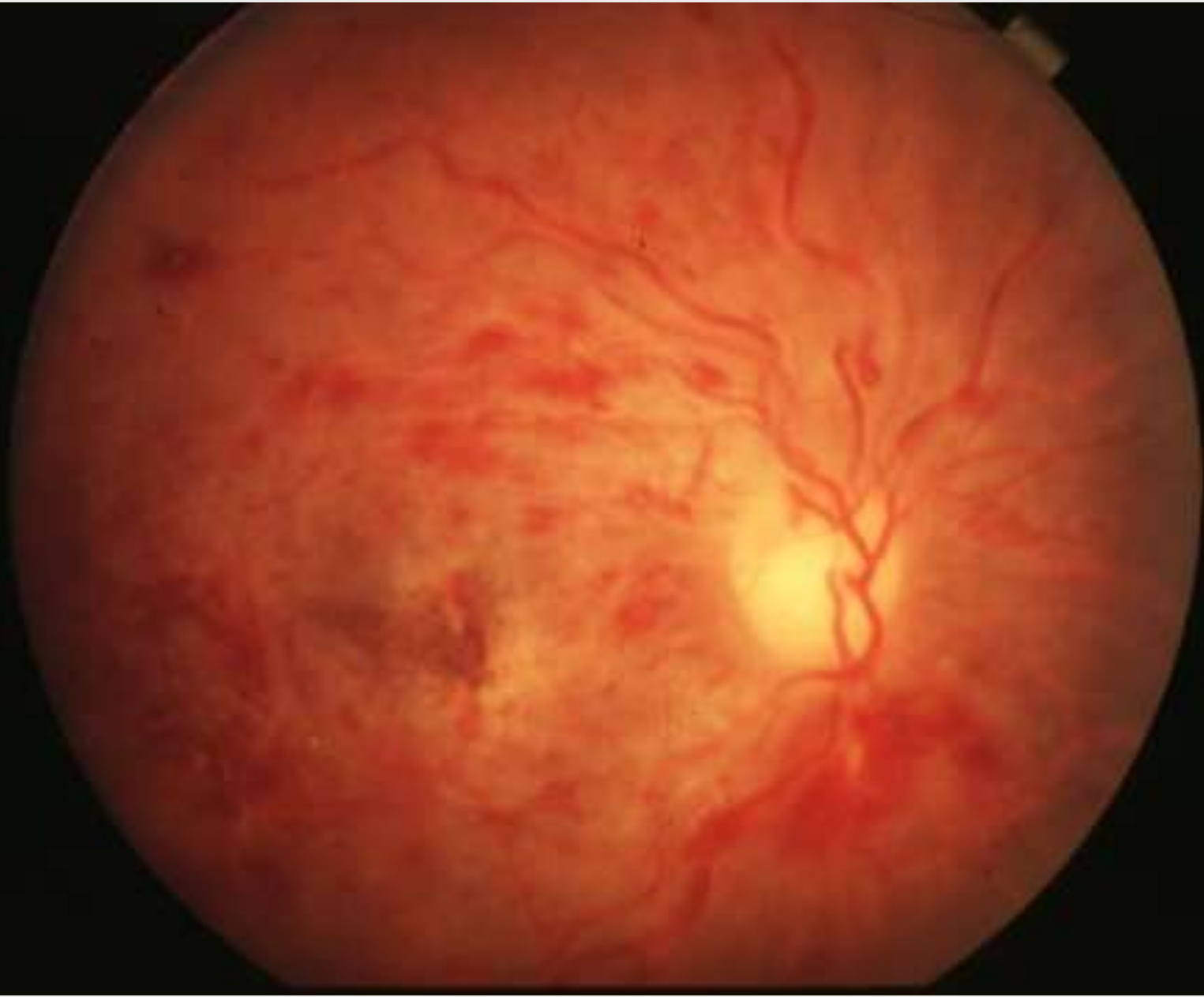



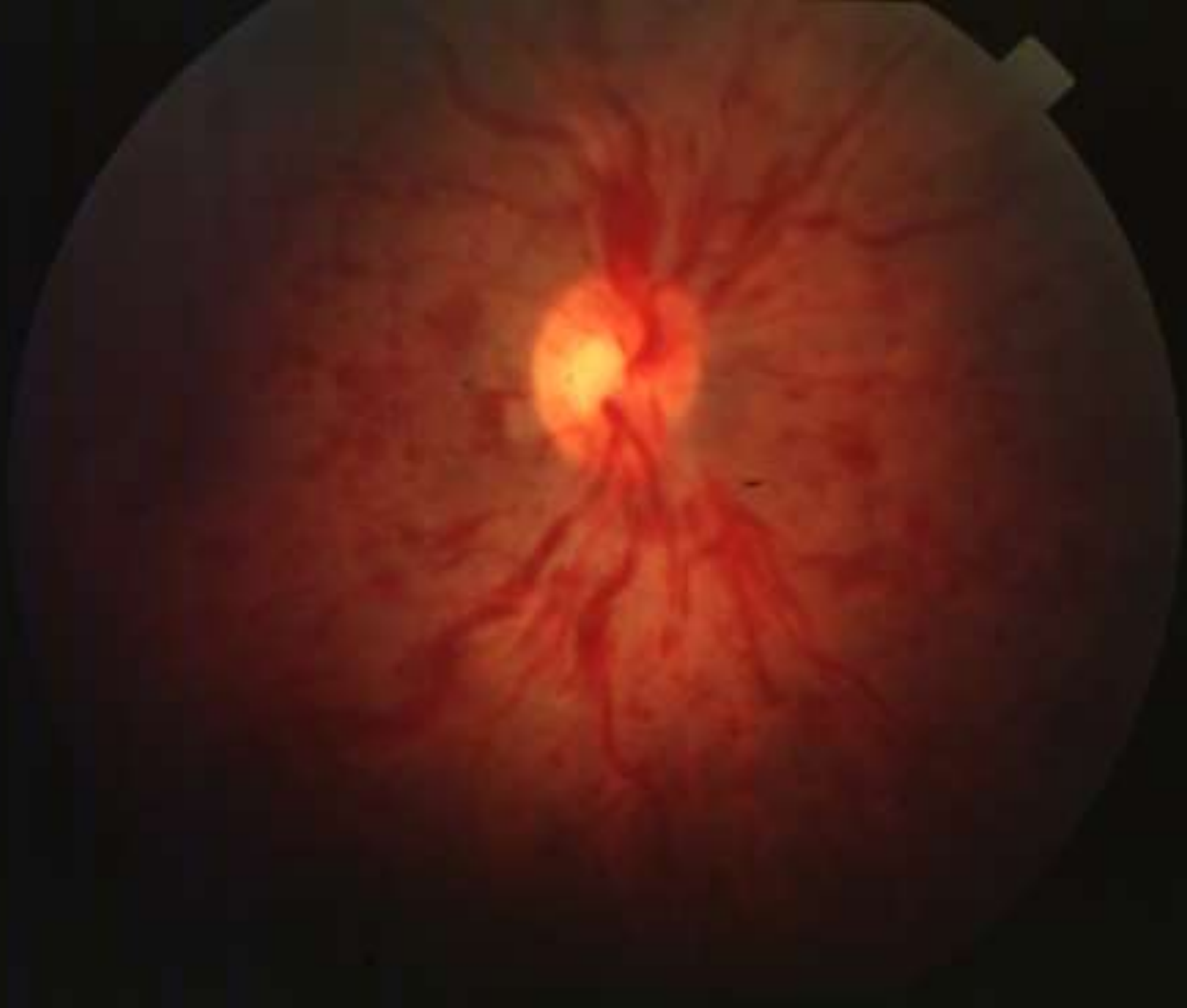0064



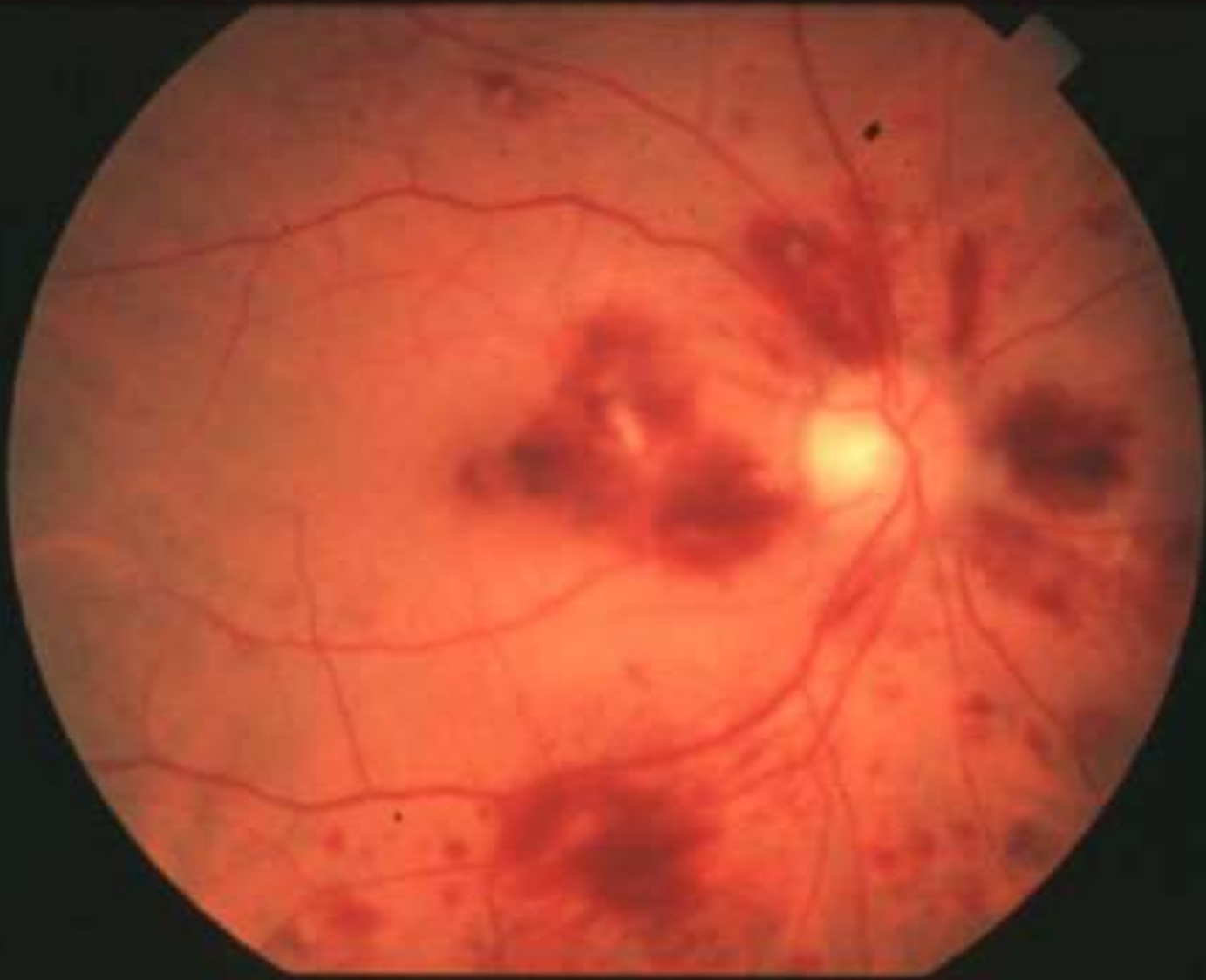6.2.3.3



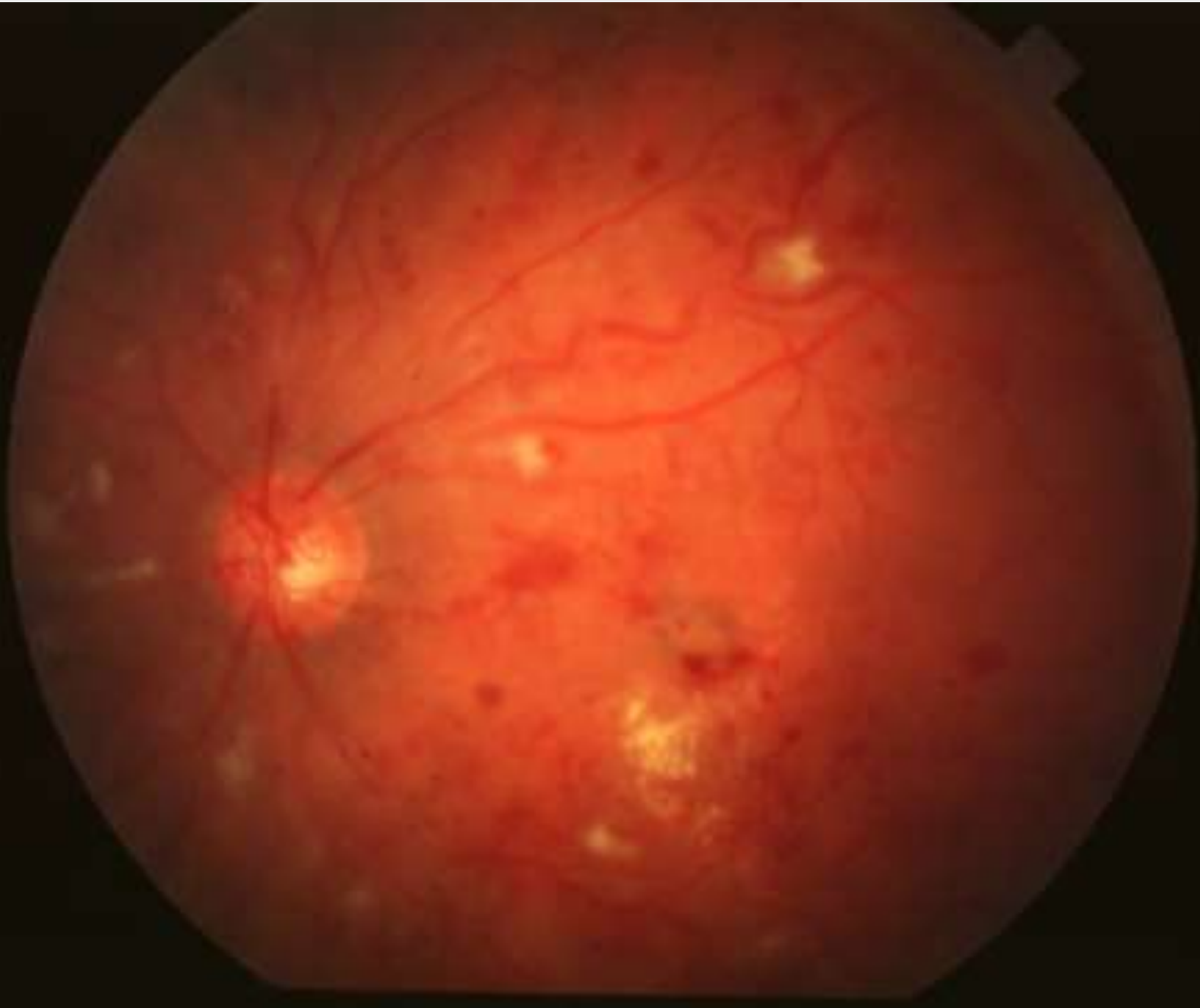0.2.3.2



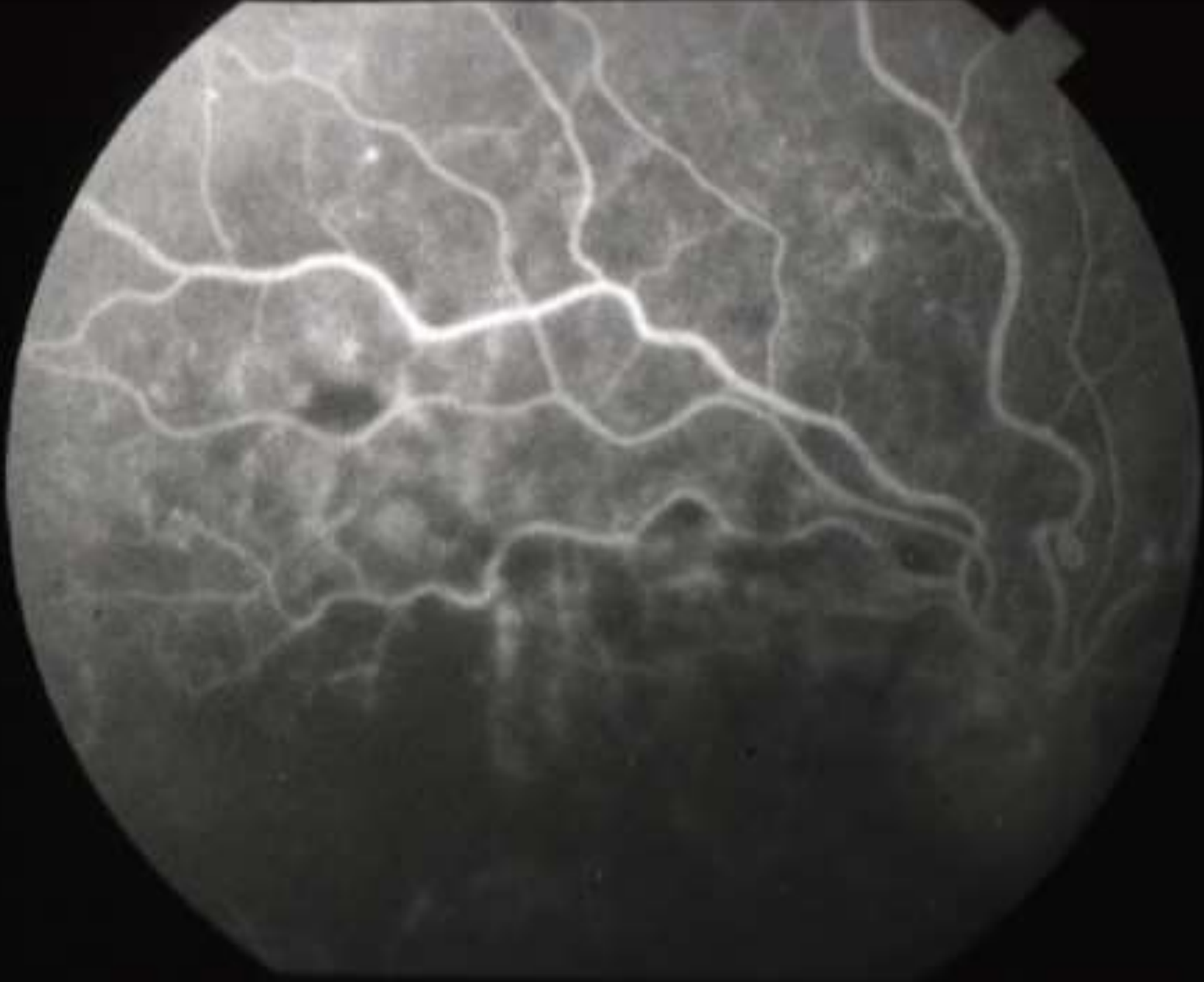
0500



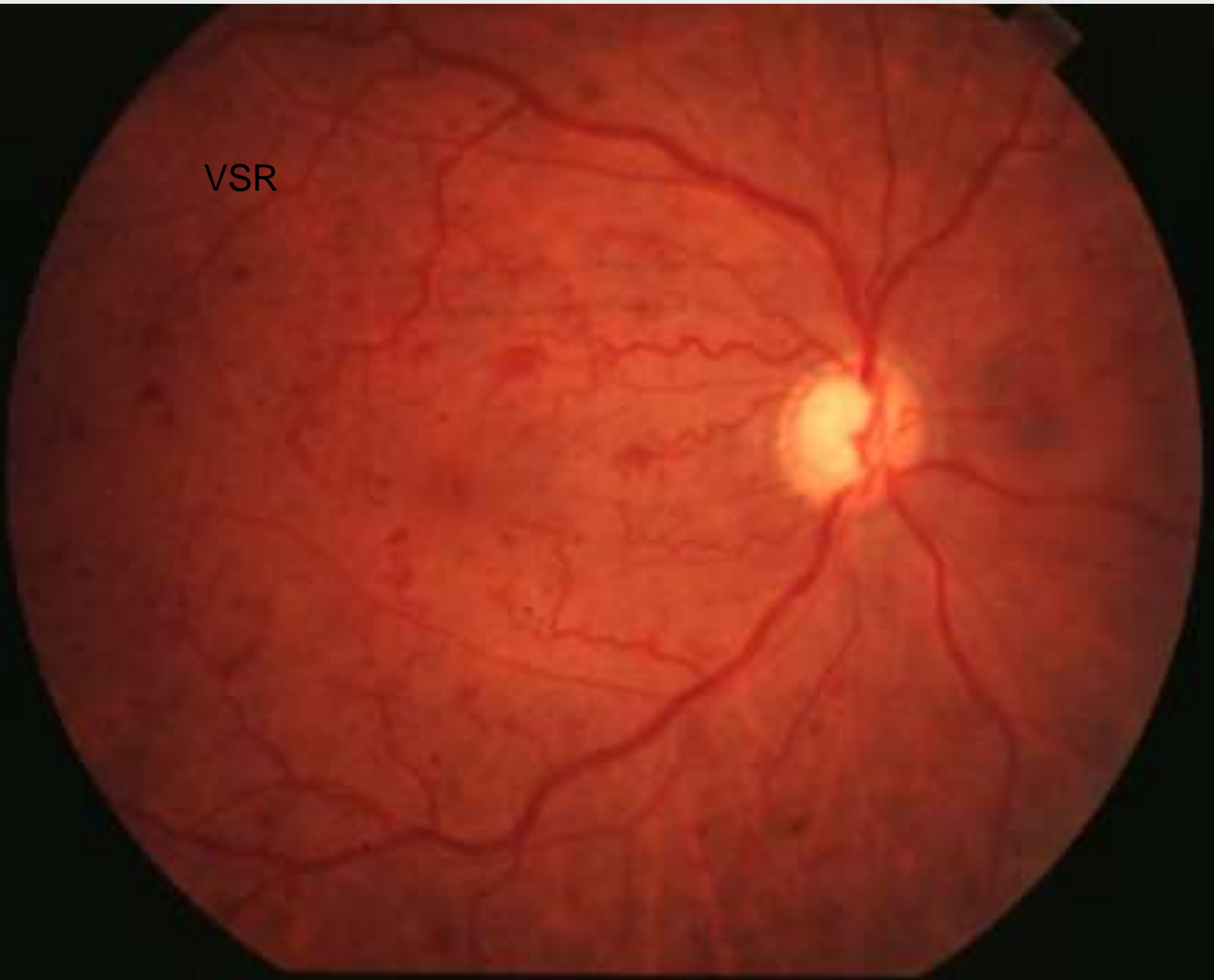
0.0.1.8



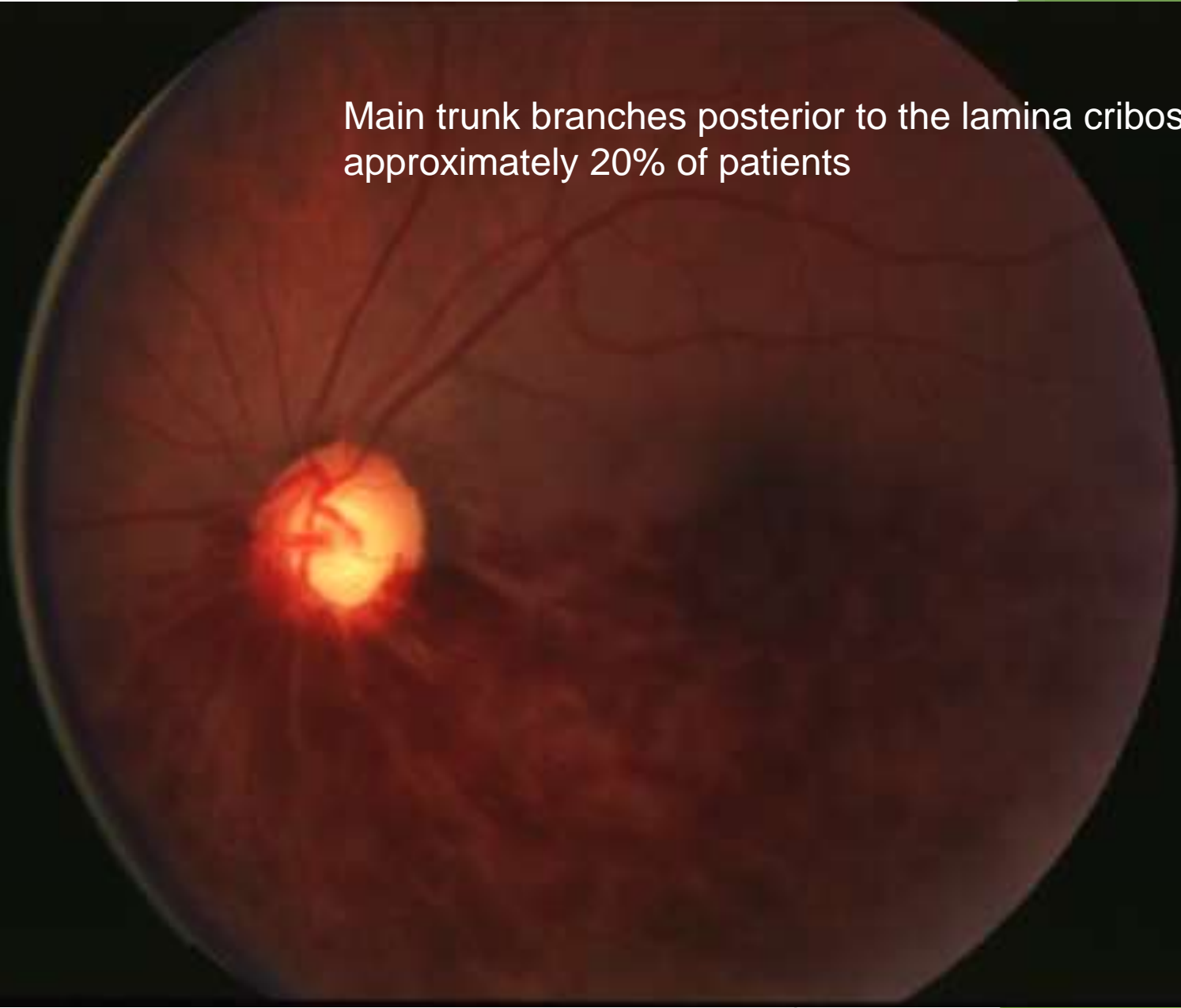
1772



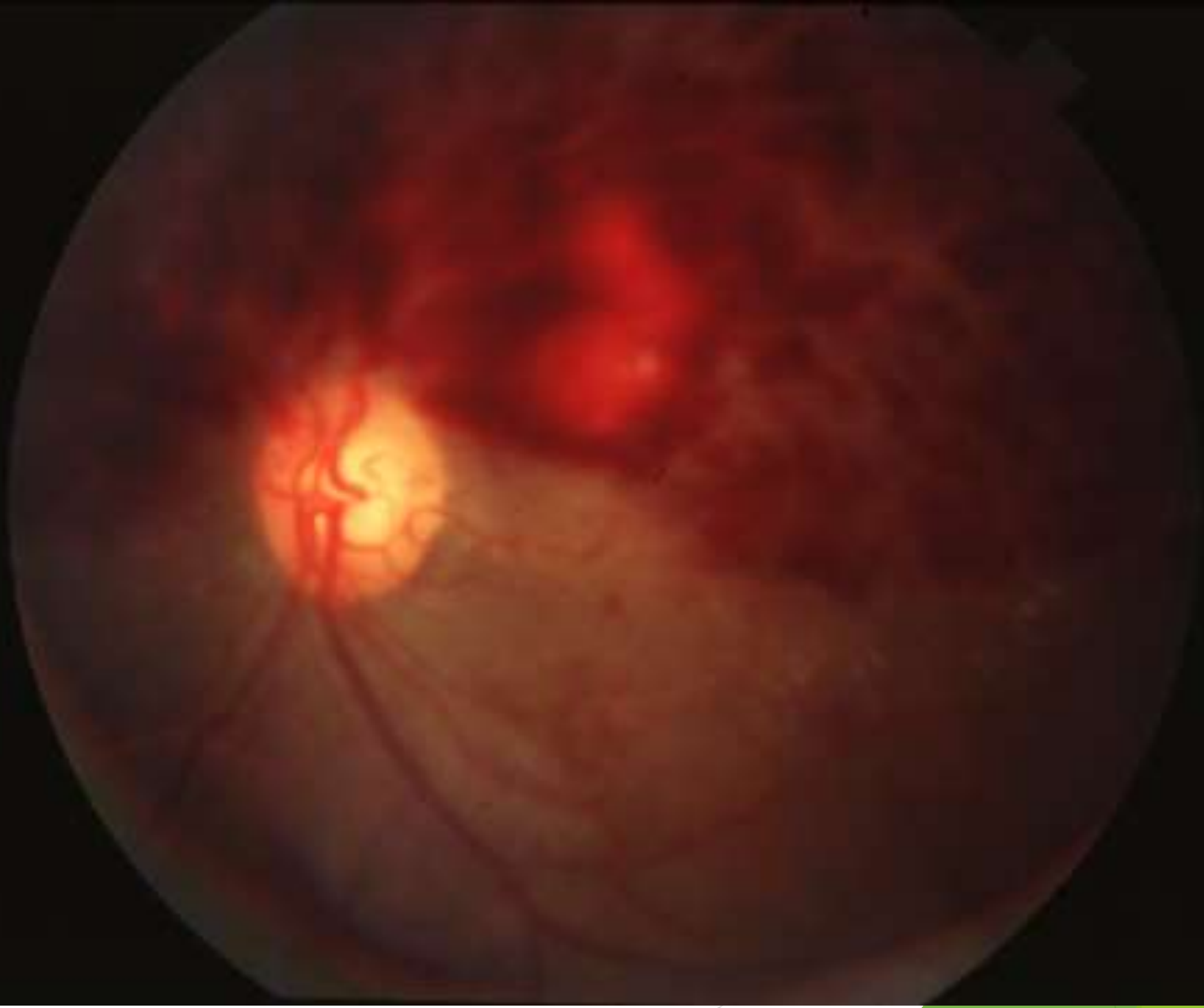VSR



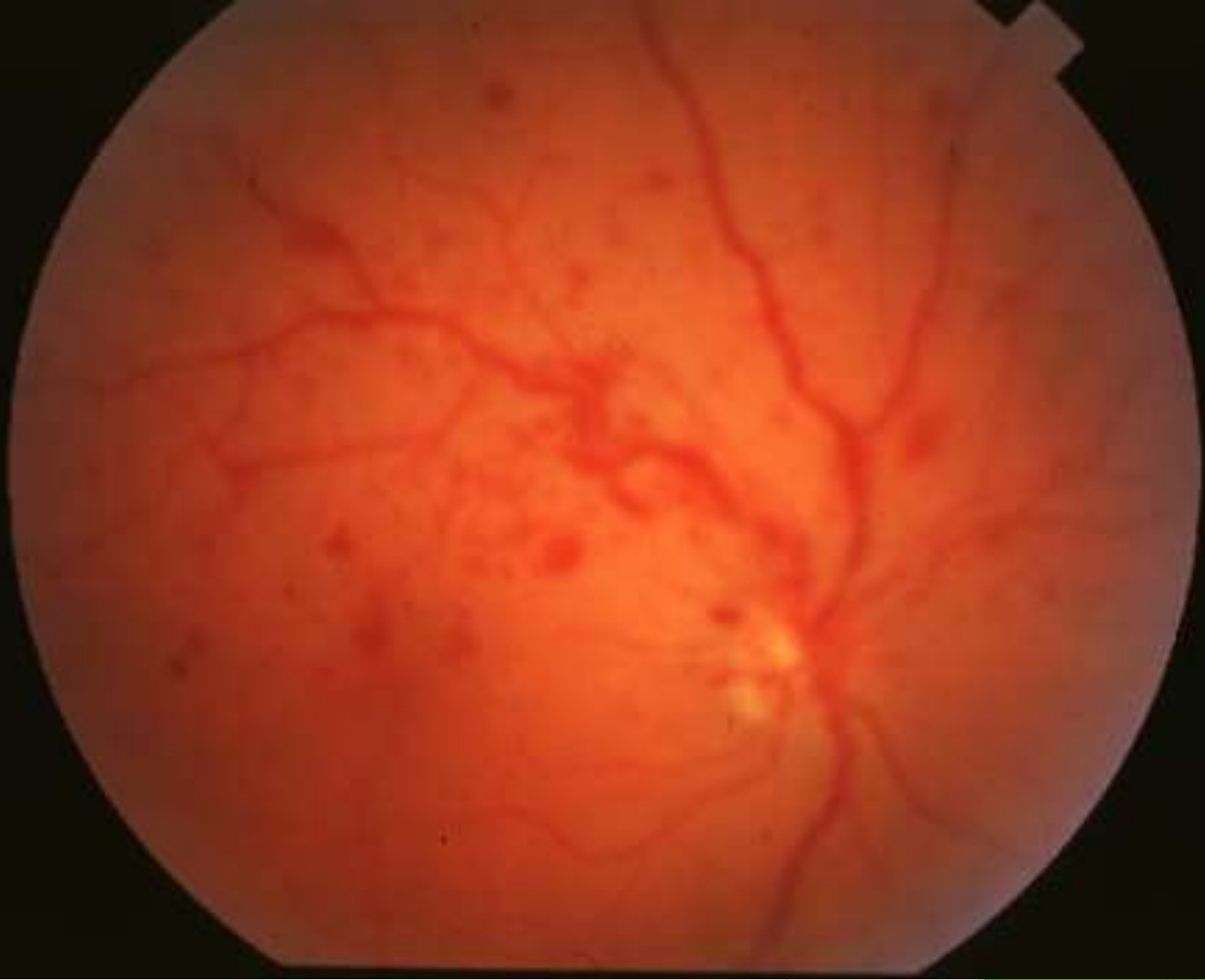Main trunk branches posterior to the lamina cribrosa in approximately 20% of patients



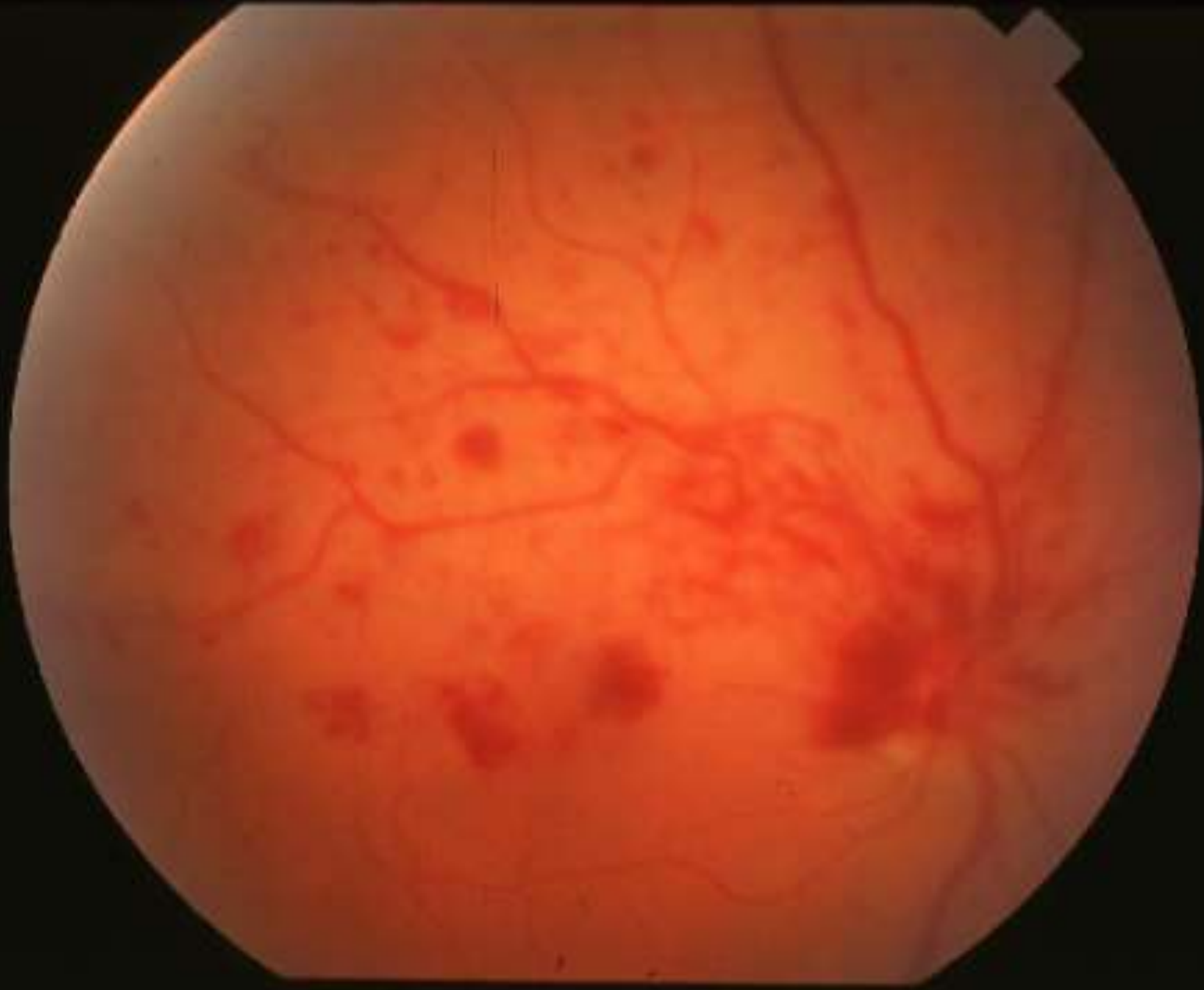0.2:4.0



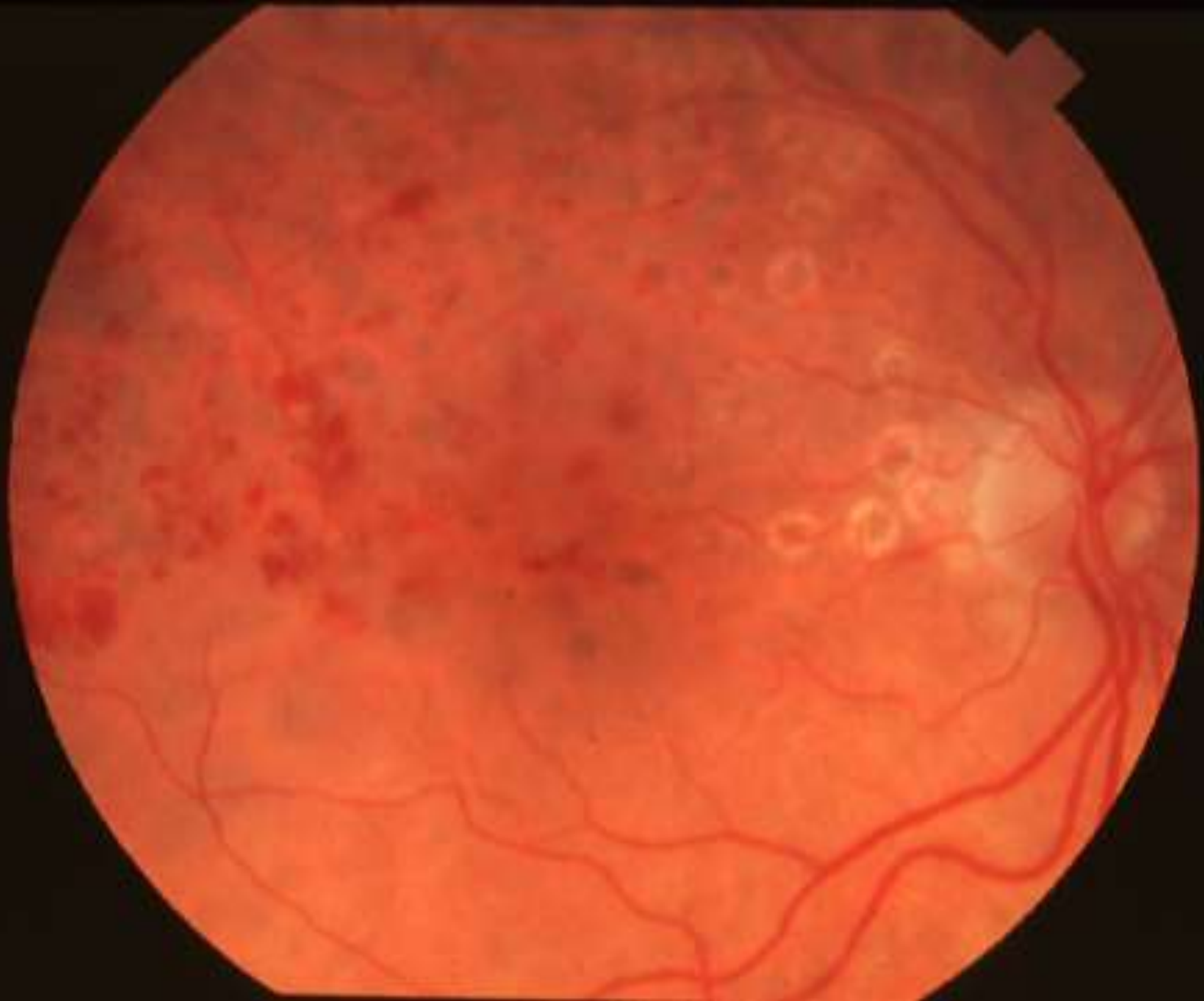4.6.3.6

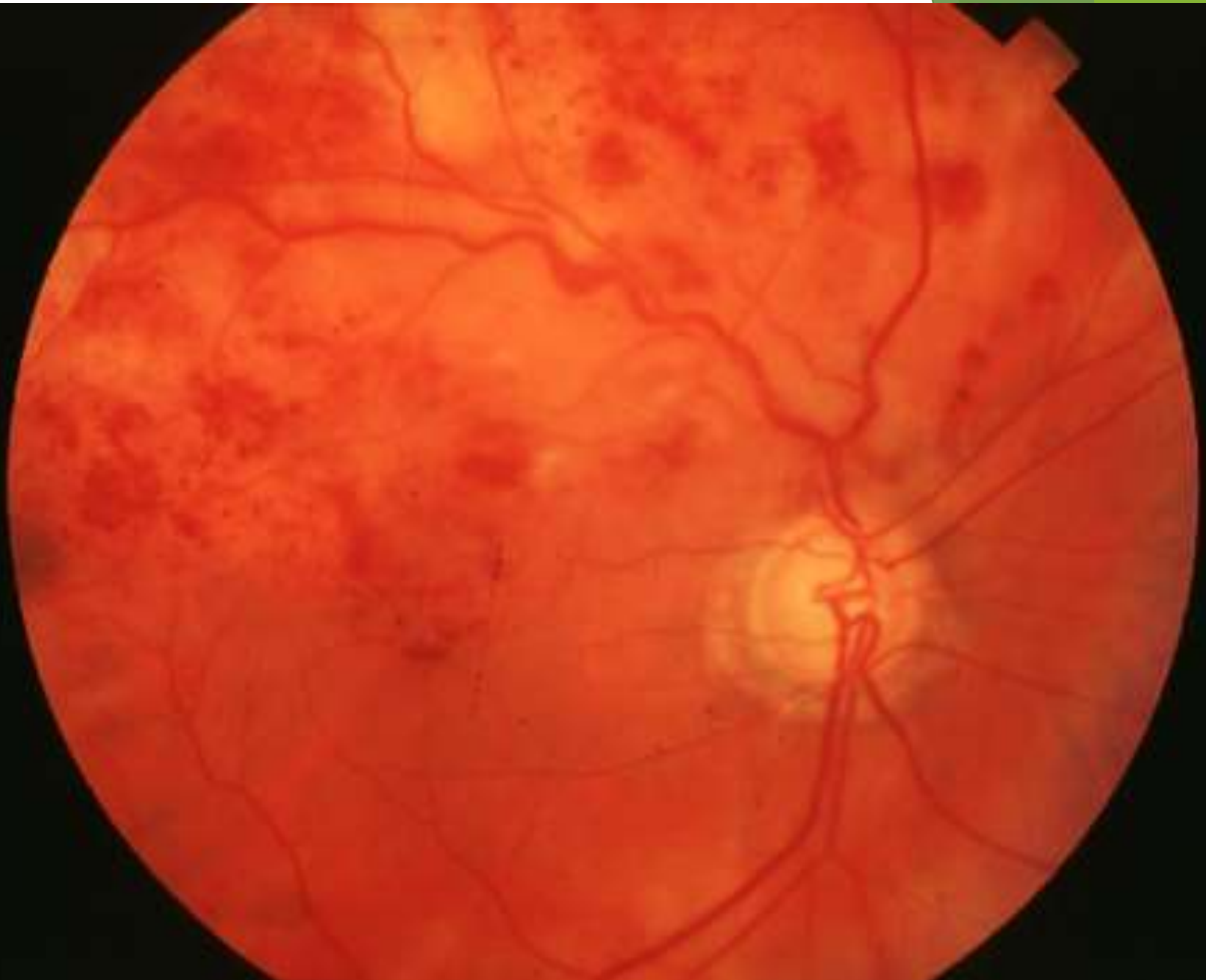


0.0.5.6



0002





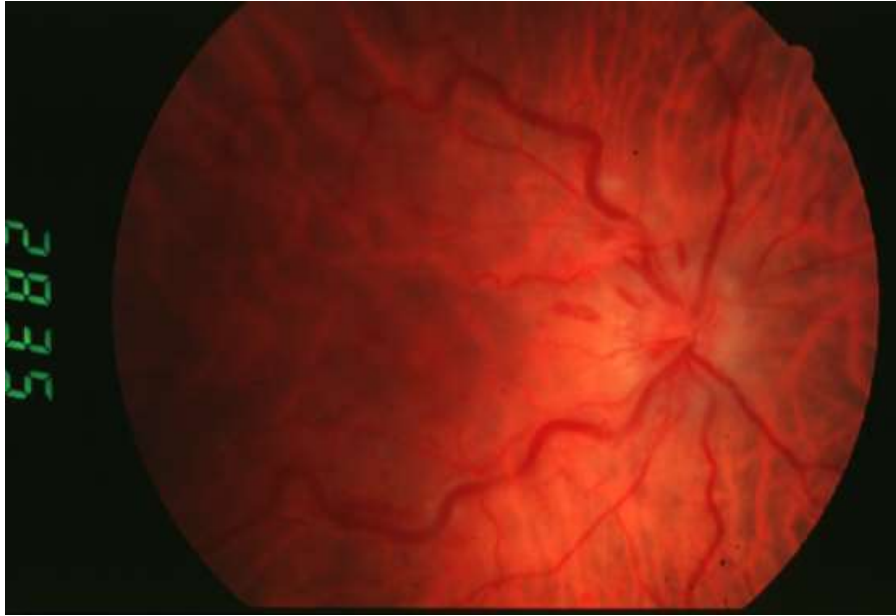
Papillophlebitis

- ▶ May be an inflammatory variant of CRVO (f 2x m). Often strikes at a younger age, but not always
- ▶ Some debate if it is even a separate condition or if it is just a very mild CRVO
- ▶ Disc edema typically out of proportion with retinal hemorrhaging, 4 quadrant hemorrhaging out to periphery
- ▶ Usually mild VA reduction to around the 20/30 level but can be worse

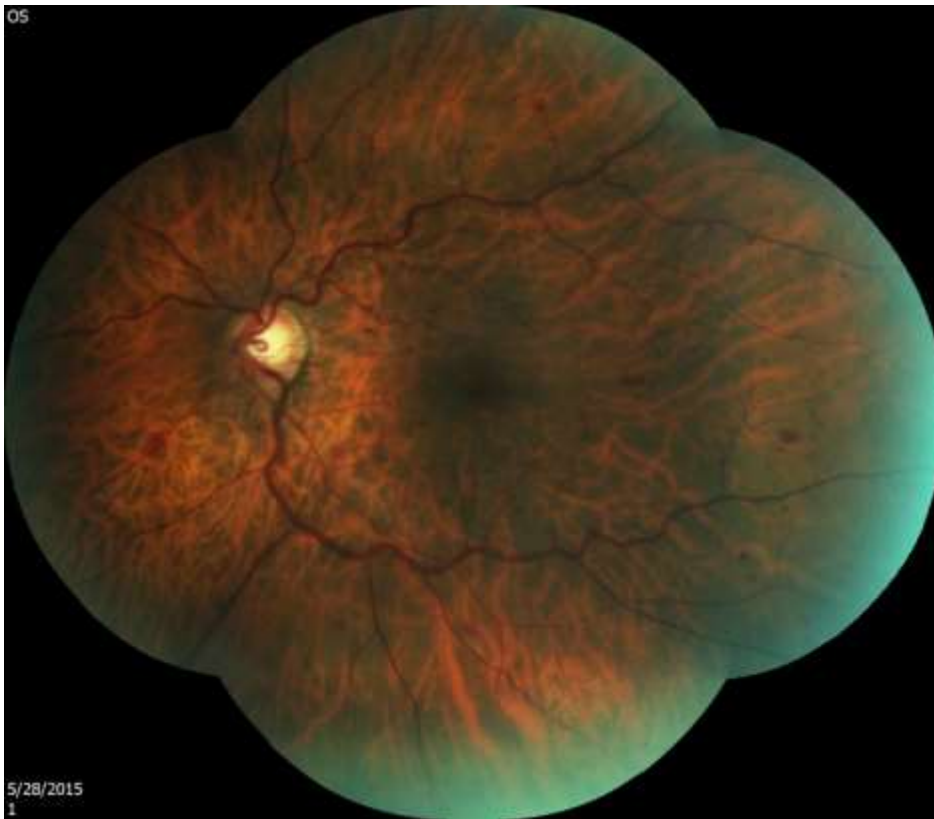Papillophlebitis

- ▶ Often a vague prodrome of scintillating, colored lights with visual disturbances
- ▶ Enlarged blind spot on the visual field
- ▶ Dilated and tortuous veins
- ▶ Condition is self limiting over the course of several months and a complete recovery is the norm
- ▶ May be related to APA syndrome, other less common systemic conditions, or may have no systemic association

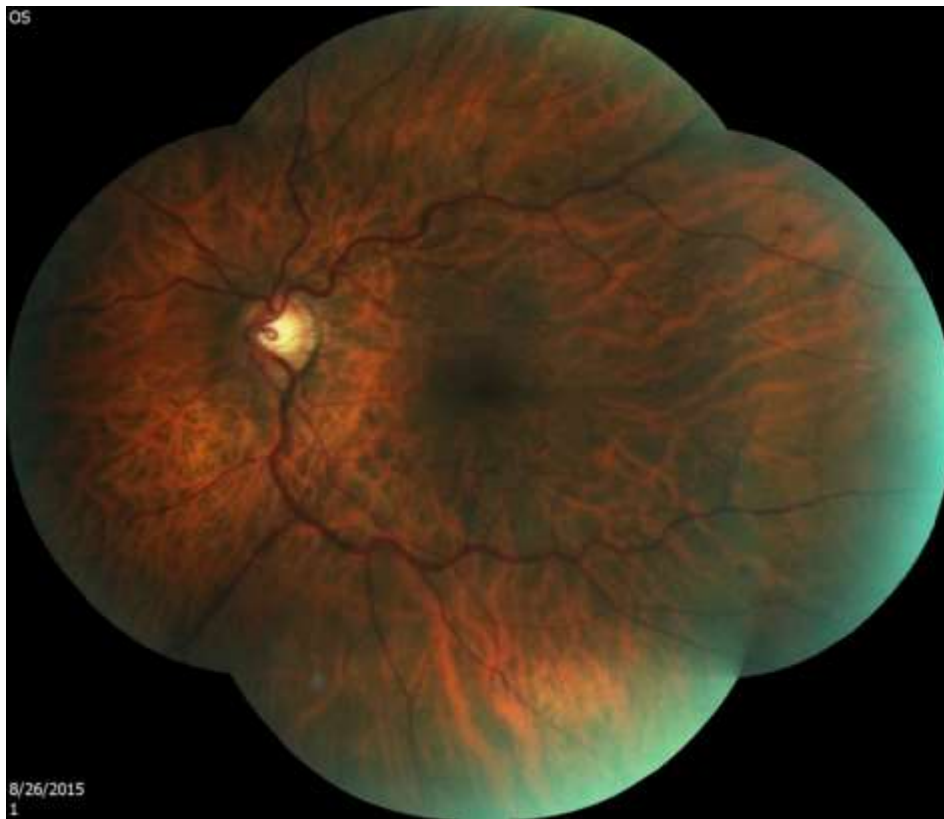Papillophlebitis



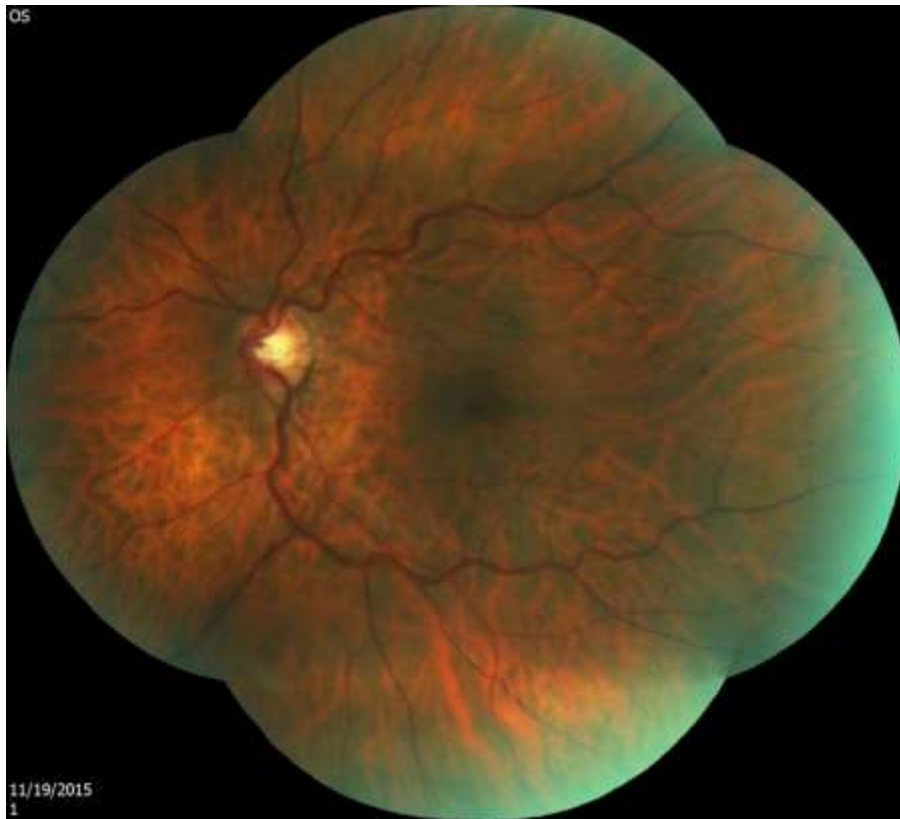Papillophlebitis



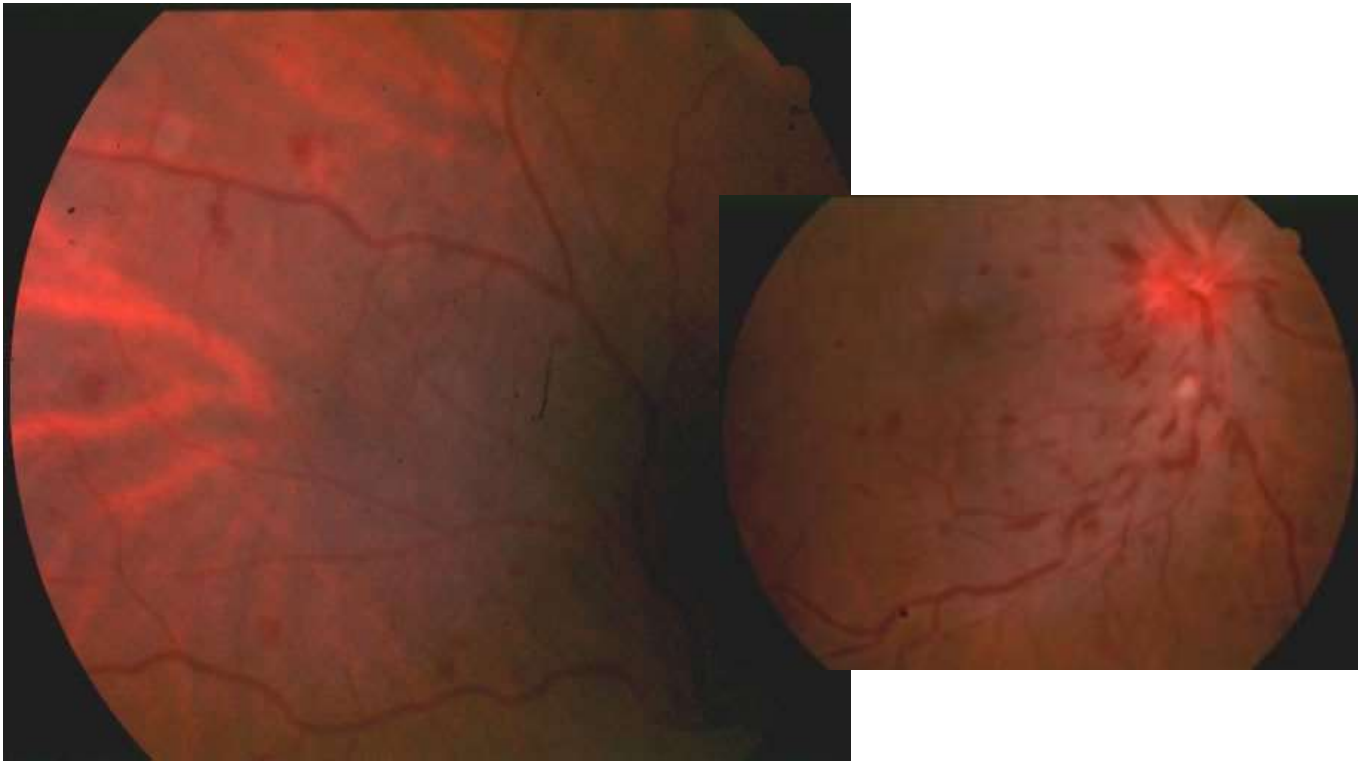
Papillophlebitis FU



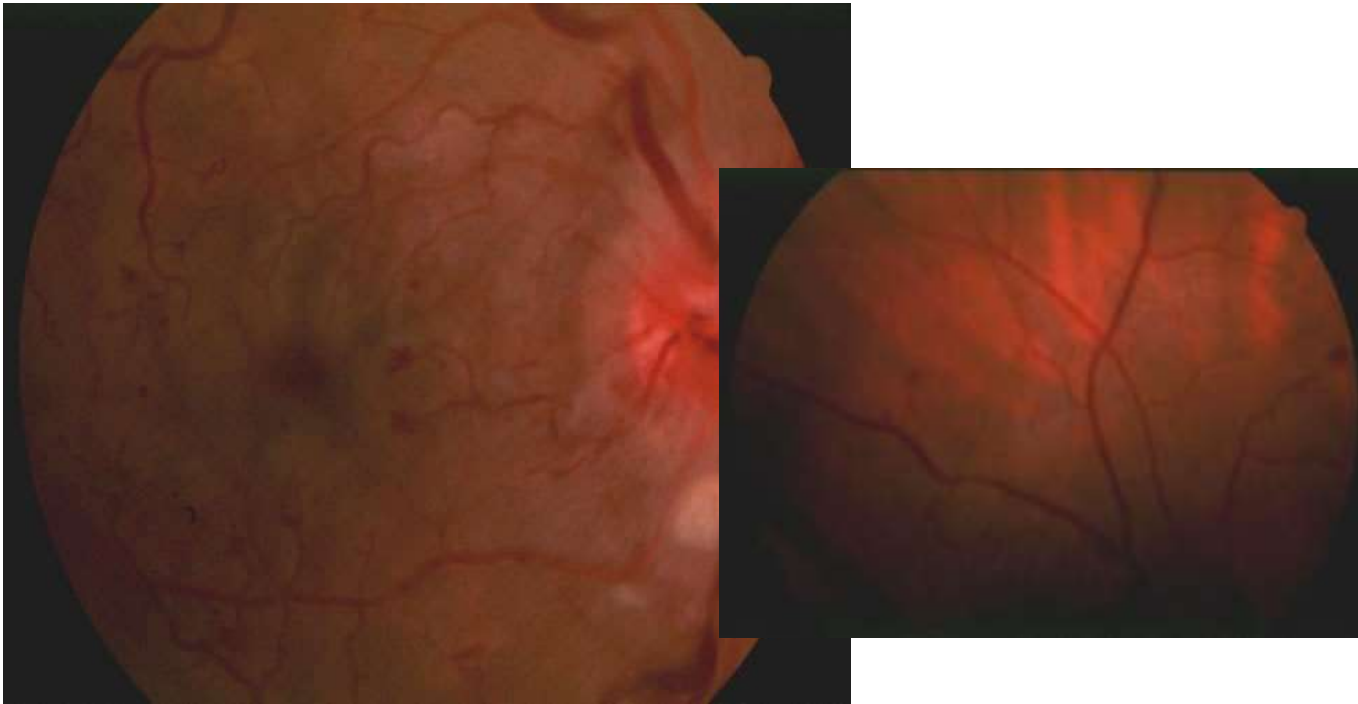
Papillophlebitis FU



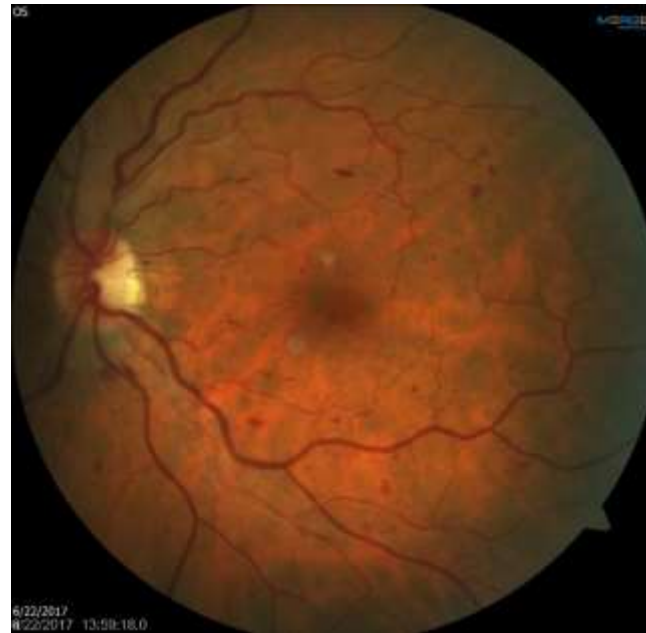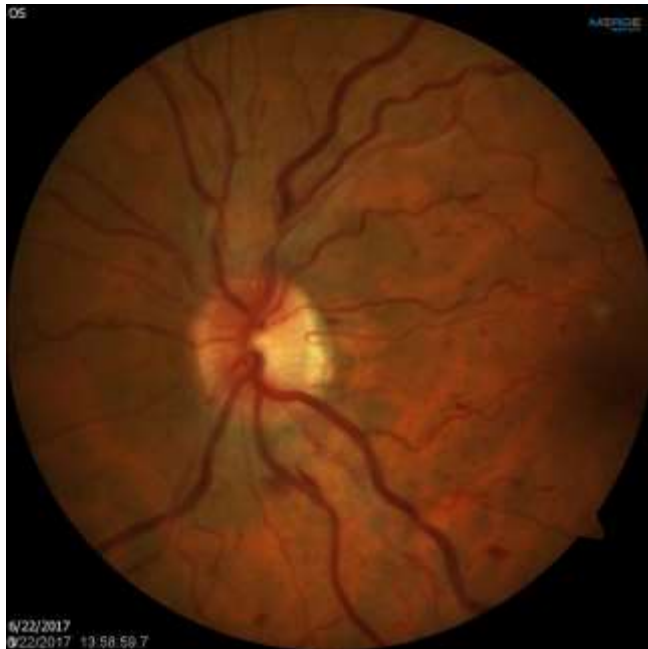Papillophlebitis



Papillophlebitis



Papillophlebitis



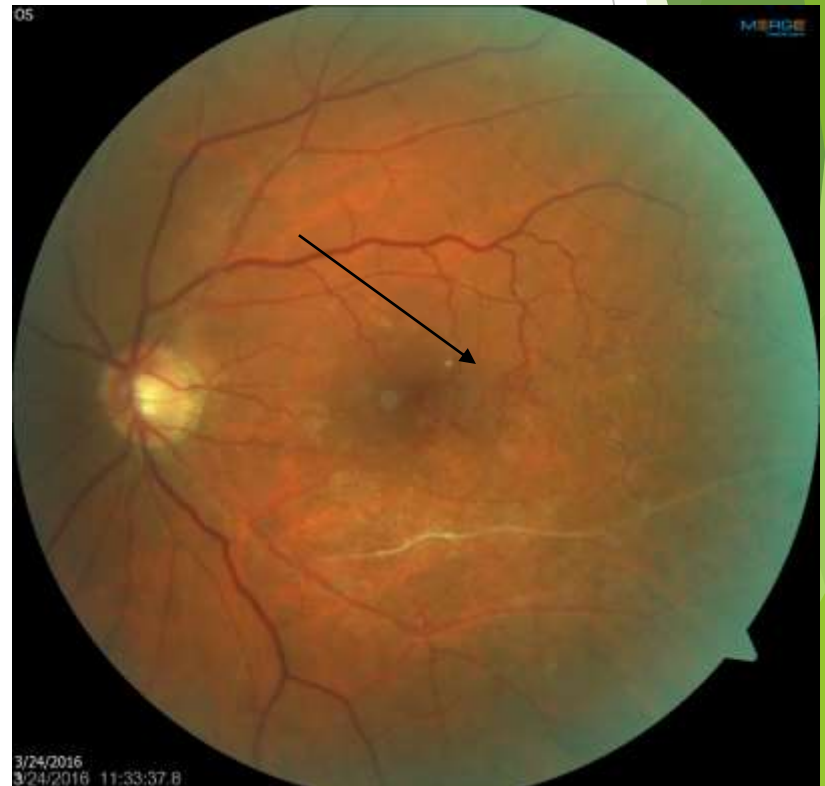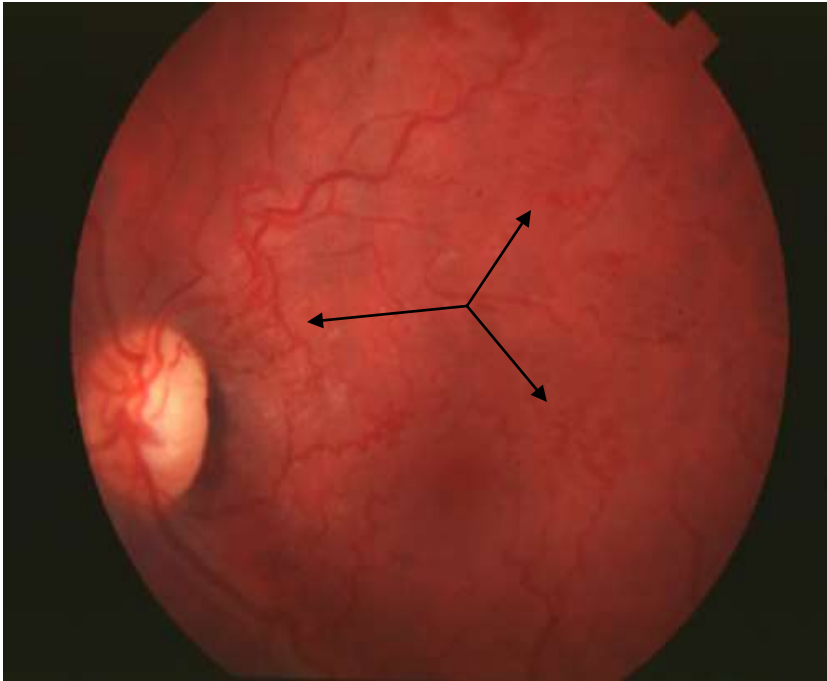
BRVO

- ▶ Rarely ischemic, commonly non-ischemic.
- ▶ VA compromised if edema or blood reaches the macula or if there is long term macular ischemia
- ▶ Neo more rare, NVD/NVE >NVI
- ▶ 98% temporal. *Why?
- ▶ Prevalence in US of .6%

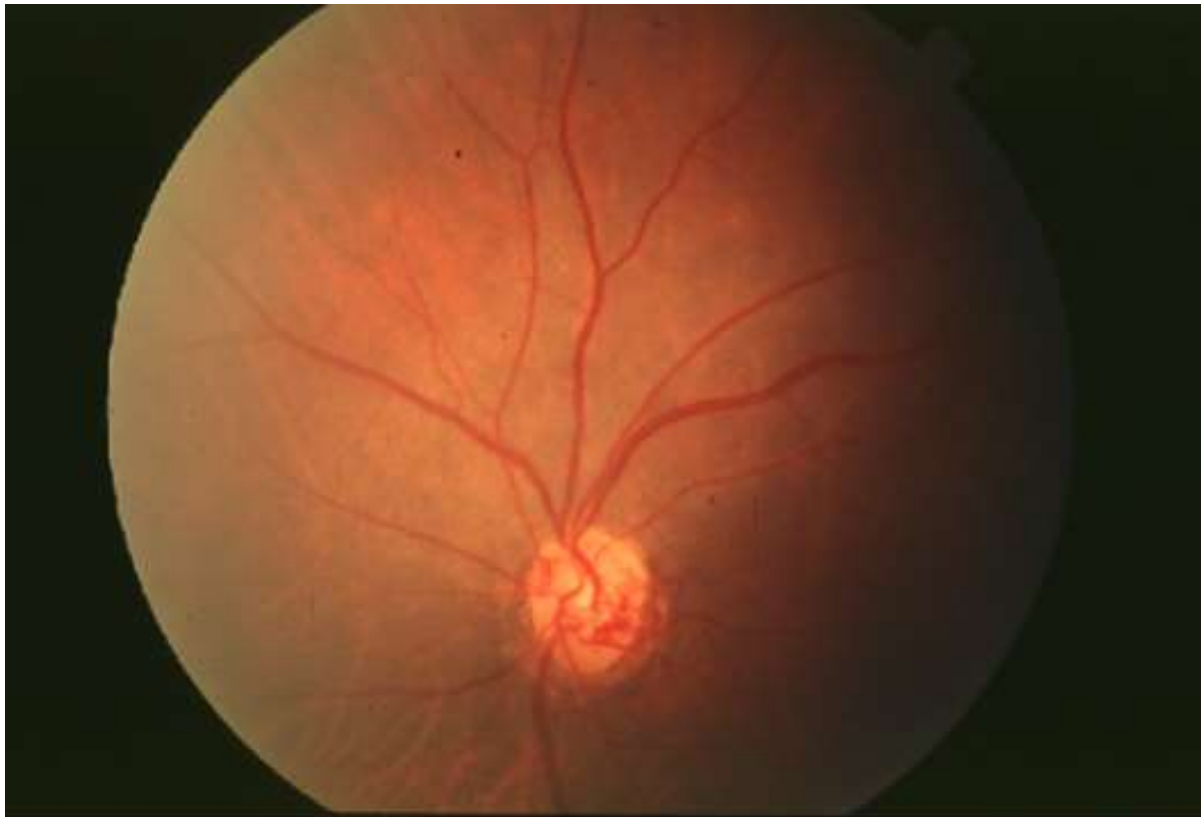
BRVO

- ▶ Spontaneous improvement in vision can occur as the macular edema resolves (over 1/3 return to 20/40 or better)
- ▶ Collateral vs. NV
- ▶ Collaterals form over 6-24 months then often regress and close, except for the largest ones. Can also form after CRVO

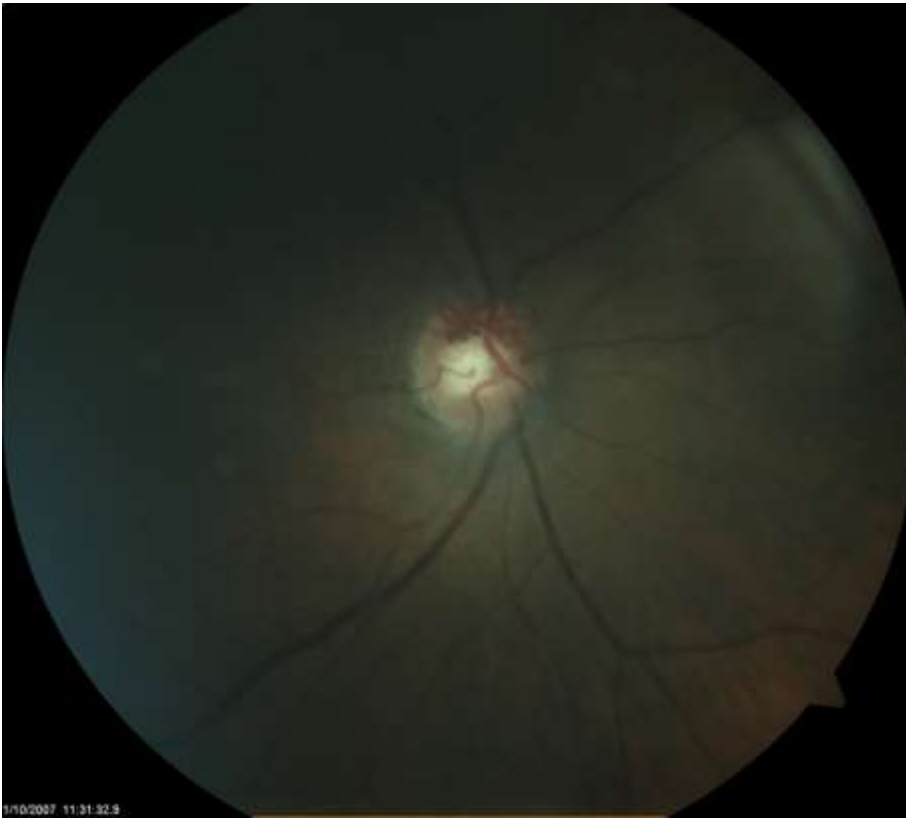Collaterals



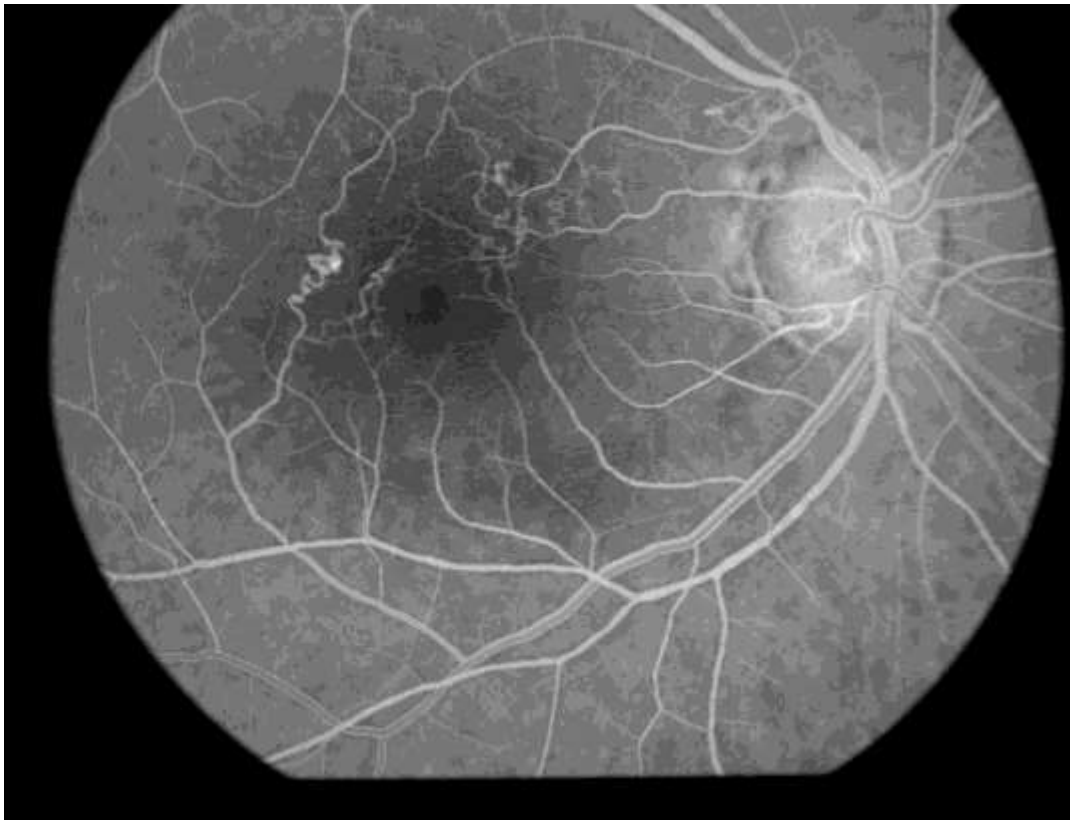Collaterals



Collaterals



Collaterals IVFA courtesy Dr. Mohammad Rafietarry



BRVO treatment

- ▶ Historically: Grid - focal laser therapy if VA < 20/40
- ▶ Often wait a few months to see if improvement occurs without treatment (which it frequently does)

- ▶ Treatment has changed, however.....

Intravitreal kenalog

- ▶ SCORE study
 - ▶ Grid laser vs. 1mg/ml kenalog vs. 4mg / ml kenalog
 - ▶ After six months:
- ▶ Grid - focal laser equal to steroid injection

Intravitreal Avastin / Lucentis / Eylea

- ▶ BRAVO study (Lucentis) At six months, gain of.....
- ▶ .3mg/ml injection vs. .5mg/ml injection vs. sham injection
 - 17 letters on EDRS chart
 - 18 letters
 - 7 letters

Eylea vs. Grid focal laser

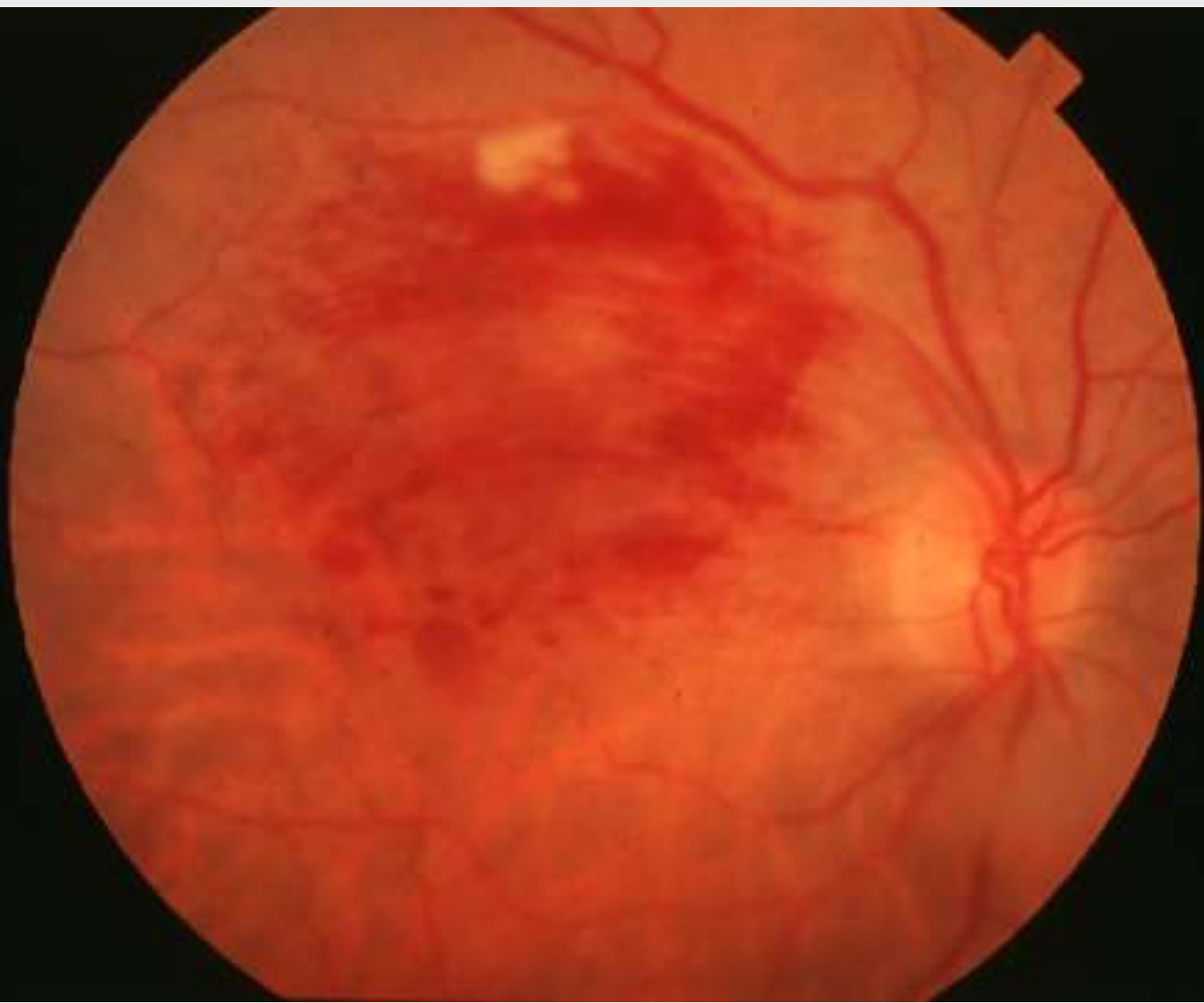- ▶ VIBRANT study of Eylea vs. laser in BRVO
- ▶ 183 patients randomized
- ▶ Assessed at 24 weeks
- ▶ 53% of Eylea group gained 15 or more letters
- ▶ 27% of grid / focal laser group gained 15 or more letters

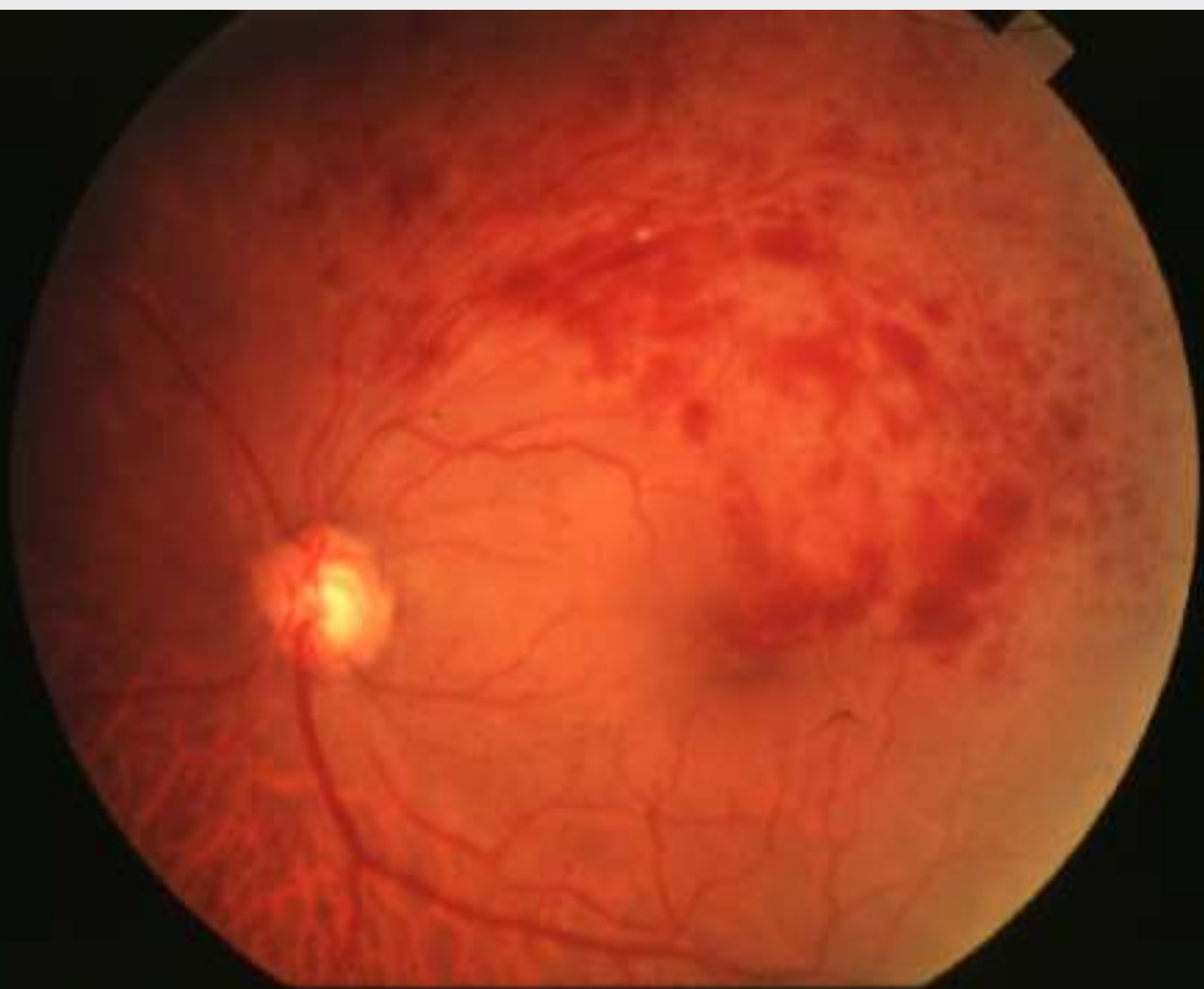
Treatment

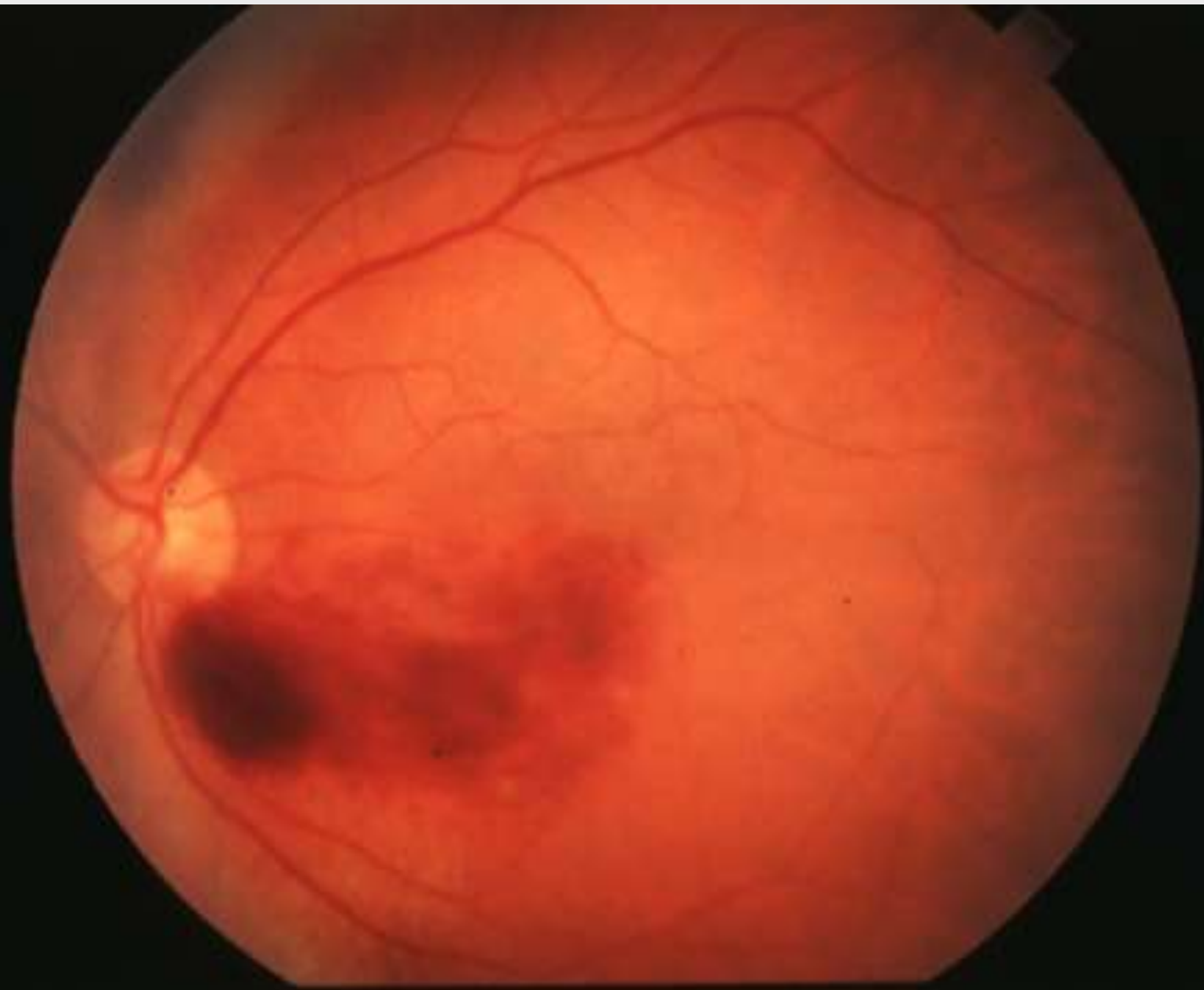
- ▶ So modern management is early and prolonged (as needed) anti-VEGF injections in the presence of any significant macular edema
- ▶ Grid / focal laser therapy can be added in recalcitrant cases
- ▶ Can still be first line therapy if difficulty with travel, cost, etc.

Cost factors for perspective.....

- ▶ Treating BRVO induced macular edema with Lucentis costs over \$13,000 per year for each line of vision saved.
- ▶ The average three year treatment cost across all treatment modalities is almost \$29,000
- ▶ Total annual cost of BRVO treatment in the US is estimated to be \$4.5 billion

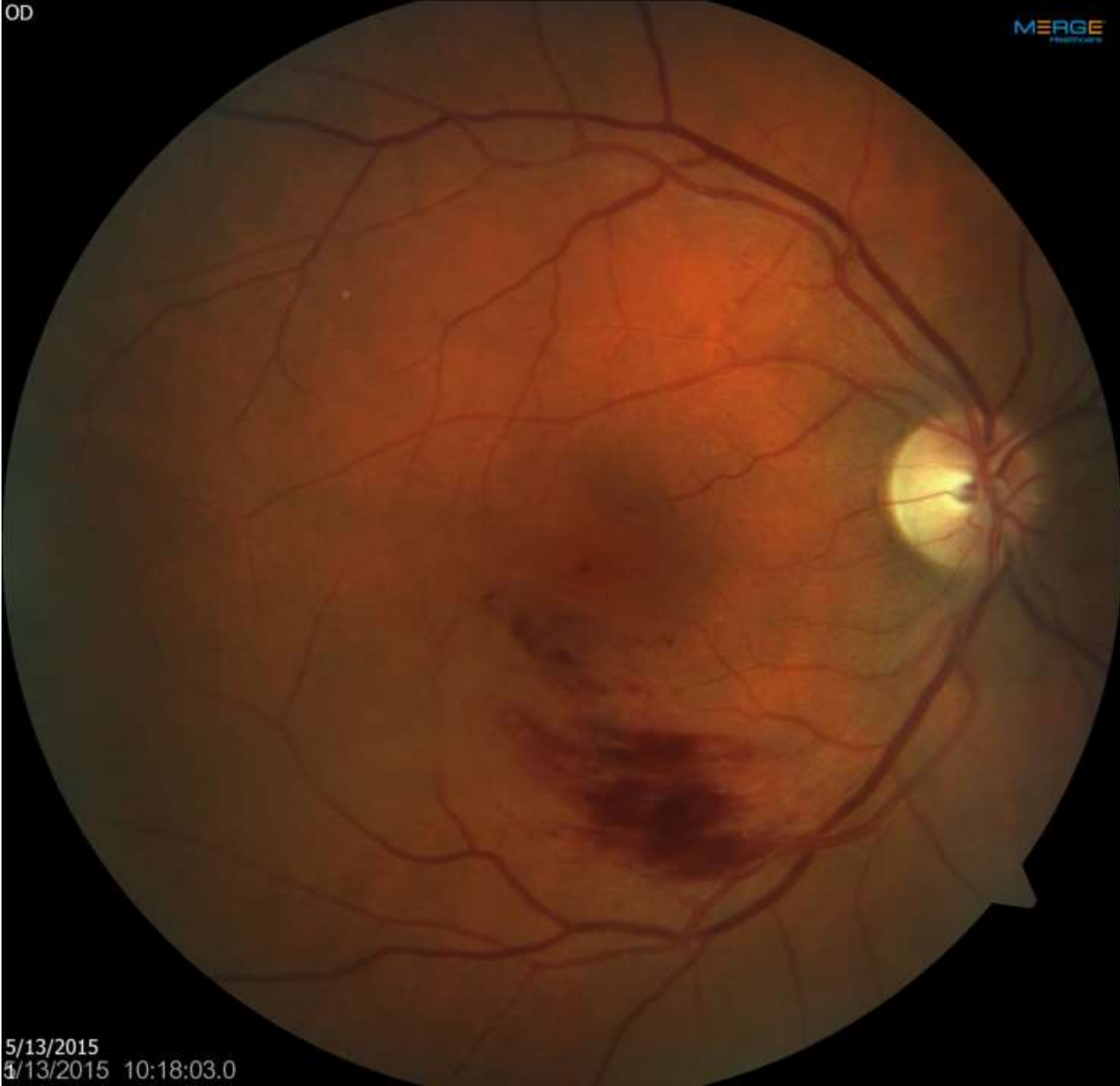





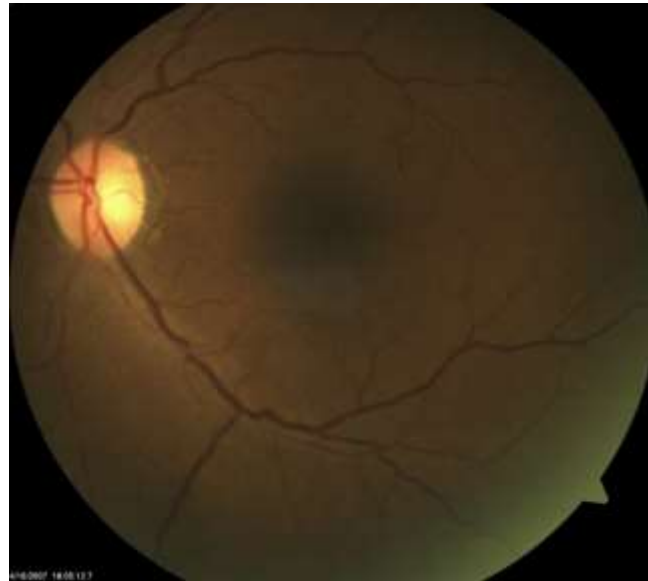
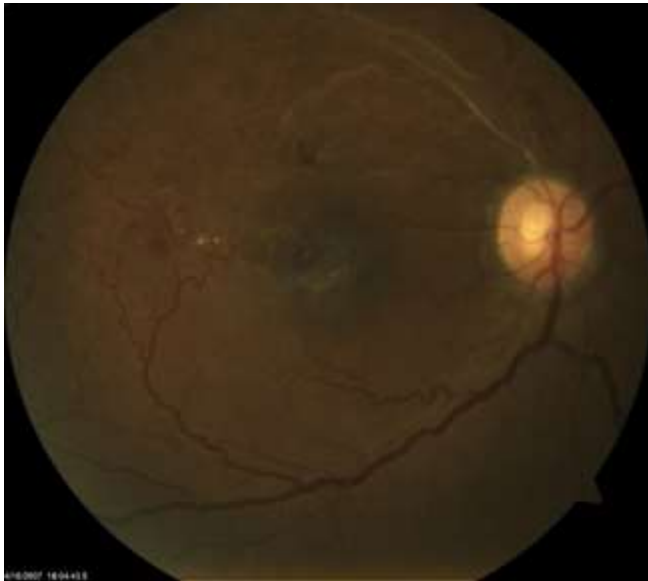OD

MERGE
PHARMACEUTICALS

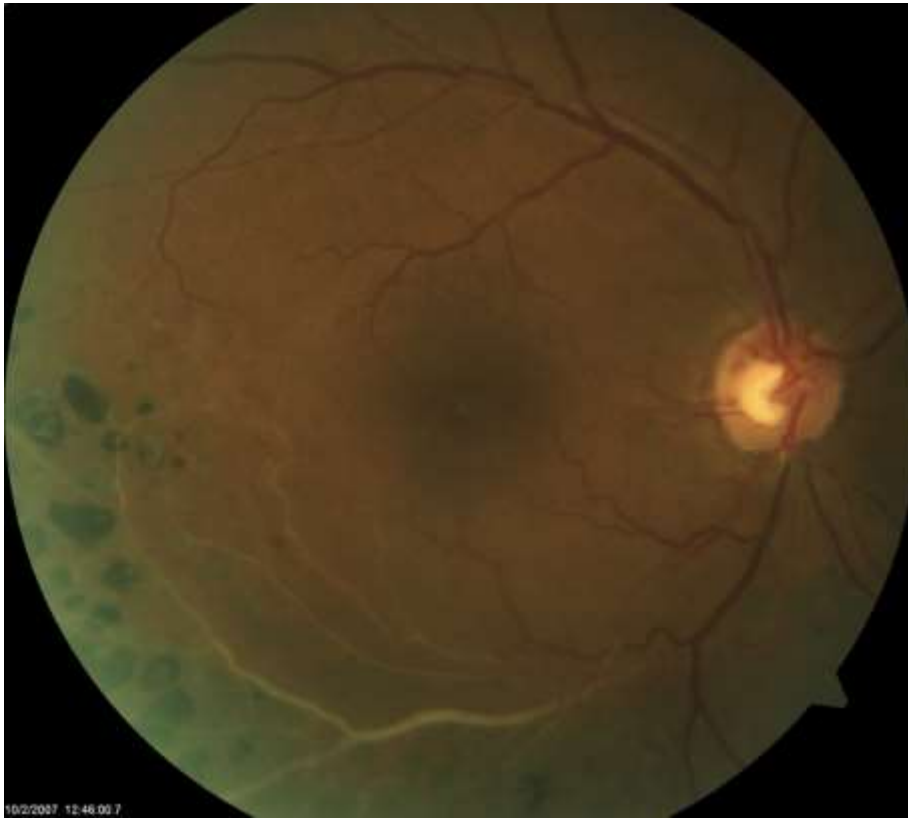

5/13/2015
5/13/2015 10:18:03.0

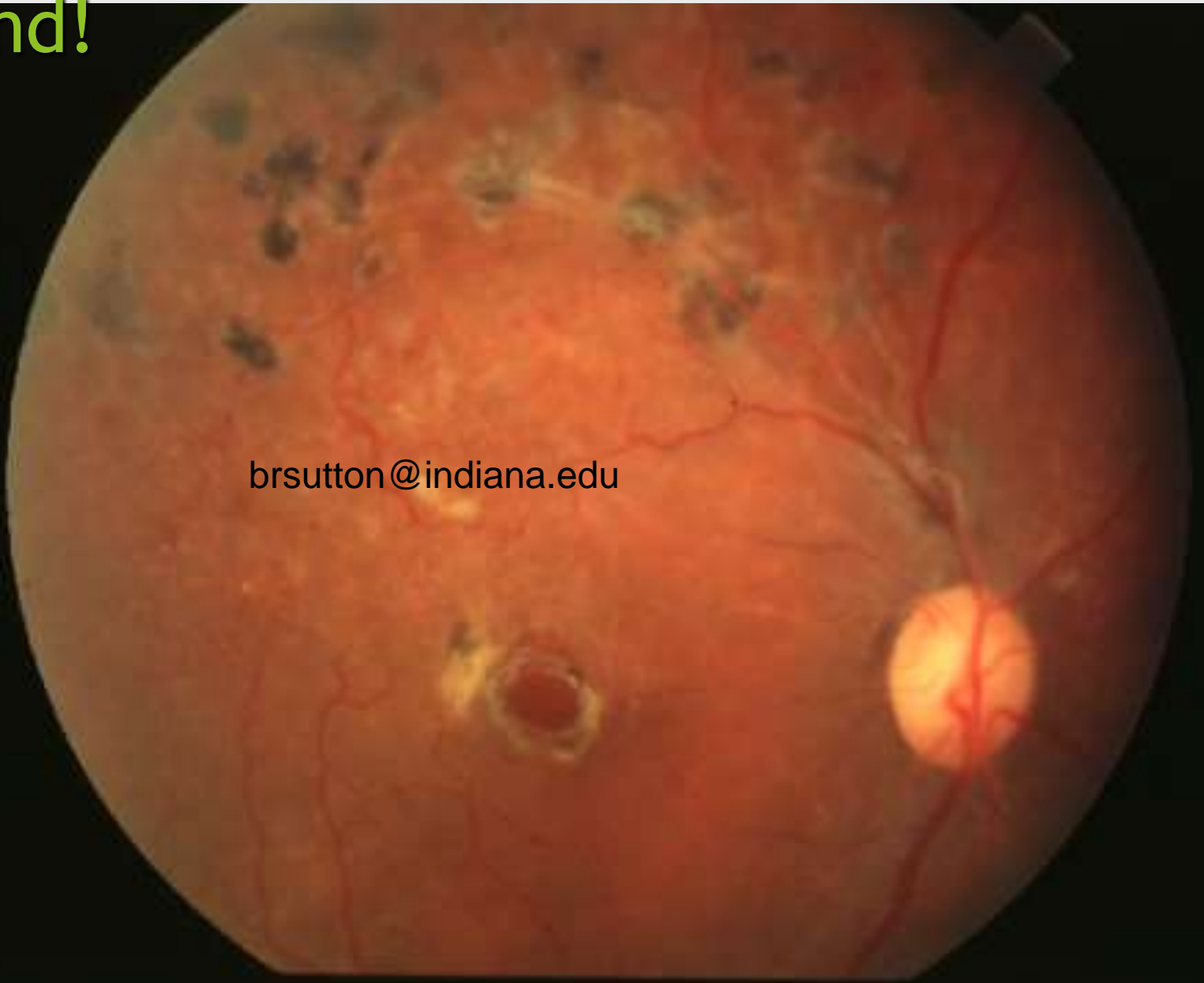
Old BRVO



BRVO S/P laser Tx



The End!



brsutton@indiana.edu